

Pediatric Overuse Injuries in Sports

Quynh B. Hoang, MD^{a,*}, Mohammed Mortazavi, MD^b

^aSports Medicine Program, Department of Orthopedics, Children's Hospital Colorado, University of Colorado Denver Health Sciences Center, 13123 East 16th Avenue, B060, Aurora, CO 80045, USA; ^bChildren's Hospital Colorado, University of Colorado Denver Health Sciences Center, 13123 East 16th Avenue, B060, Aurora, CO 80045, USA

Keywords

• Overuse injuries • Apophysitis • Sports • Pediatric

Key Points

- Overuse injuries in youth sports are increasingly common as more children and adolescents participate in some form of athletics.
- Overuse injuries are chronic injuries that occur when repetitive stress is placed on bone, muscle or tendon without adequate time for healing and recovery.
- Familiarity and basic knowledge of common sports-related overuse injuries is important so that proper diagnosis can be made. This allows timely treatment to minimize time loss from participation and ensures a safe return to sports.
- Although management of overuse injuries are centered around relative rest and activity modifications, identifying youths at risk of these injuries is key so that education, prevention, and early diagnosis and treatment can occur.

INTRODUCTION

As more children participate in recreational or organized athletics, pediatricians are evaluating more sports-related injuries in their practice. Each year an estimated 30 million children in the United States participate in some form of organized athletics [1] and this number likely will continue to grow. Moreover, many children today are playing on multiple teams during a given season or are playing different sports throughout the year. Some children have no such thing as an “off season.” Consequently, an increase in the incidence of acute injuries and in chronic injuries related to overuse has been seen.

When repetitive stress is placed on bone, muscle, or tendon without adequate time for healing and recovery, microtrauma occur in these structures, resulting in an overuse injury. Physiologically, growing cartilage in pediatric bone is vulnerable to stress. These cartilaginous growth plates and apophyses lend to unique injury patterns that are specific to children. During times of rapid growth,

*Corresponding author. *E-mail address:* Quynh.Hoang@childrenscolorado.org

apophysitis is a common overuse injury. An apophysis is a secondary ossification center that gives contour to bone and is also the site of attachment of the muscle tendon. In a growing child, the muscles attached to these apophyses are overly tight, and when overworked, repetitive traction forces are placed on these vulnerable growth centers. The result is chronic irritation, inflammation, and microavulsions at the bone-cartilage junction. Common locations of apophysitis include the heel (Sever disease), elbow (little league elbow), and knee (Osgood-Schlatter disease). Overuse injuries to the physis and epiphysis are also common in children, particularly in the overhead athlete or the gymnast. Examples include little league shoulder and gymnast's wrist. Repetitive stress and microtrauma can also lead to overuse tendon injury (tendinitis), which is another major subset of overuse injuries in children. Some of the more common tendinitis in children that are discussed in this article include patellar tendinitis and iliotibial band tendinitis (IT syndrome), although foot and ankle tendinitis and shoulder (rotator cuff) tendinitis can also occur in young athletes. Finally, stress fractures are another example of an overuse injury. Repetitive compressive or tensile forces weaken the bone through a continuum of bone marrow edema without a visible fracture line (stress reaction) and can lead to a complete fracture (stress fracture). Once a rare phenomenon, stress fractures are being reported at a much higher incidence today with the advent of organized youth sports [2,3]. Although this article reviews only spondylolysis (stress fracture of the pars interarticularis of the vertebral body), predominant sites of stress fractures in young athletes also include the tibia, fibula, femur, metatarsals, and navicular bone in the foot [2,3]. Regardless, they all have a common denominator with a multifactorial phenomenon: training errors, biomechanics, diet, and, in girls, menstrual function.

As primary care providers, familiarity and basic knowledge of some common sports-related overuse injuries become important as increasingly more children participate in sports. That way, proper diagnosis can be made and timely treatment or referral to a sports medicine specialist can commence to minimize the time lost from participation.

UPPER EXTREMITY INJURIES

Little league shoulder (proximal humerus epiphysitis)

Little league shoulder refers to an overuse injury of the proximal humerus in overhead athletes with open growth plates. It is believed to result from repetitive microtrauma to the proximal humeral epiphysis and physis from constant traction and rotational torque stresses during throwing and overhead activities [4,5]. Although most commonly seen in male baseball players, little league shoulder (or *proximal humeral epiphysitis*) can affect all overhead athletes, including tennis players, swimmers, volleyball players and even gymnasts [6,7]. It commonly occurs between 11 and 16 years of age [4,8], when the proximal humeral physis growth is at its peak, leaving it vulnerable to stress injury. In baseball players, risk factors that contribute to the development of little league shoulder include improper pitching mechanics and frequent pitching without rest periods [4].

The typical patient presents with progressive pain over the lateral aspect of the proximal humerus that occurs with throwing and overhead activities [4,8]. Physical examination shows tenderness over the proximal and lateral aspect of the humerus in approximately 70% of the patients [8]. Thus, a normal examination does not preclude the diagnosis, and a classic history of pain with throwing or overhead activity is key.

Radiographs should be ordered to confirm the diagnosis and also help rule out other causes of shoulder pain. Findings on radiographs include widening, sclerosis, and irregularity of the humeral physis, which can best be appreciated on anteroposterior view of the shoulder in external rotation (Fig. 1).

Obtaining comparison views of the unaffected shoulder is often helpful to confirm the diagnosis if radiograph findings are subtle. If radiograph findings are negative and clinical suspicion remains high, further imaging with either MRI or bone scan may be considered.

Treatment of little league shoulder includes rest from throwing and overhead activities until pain is significantly decreased. On average this takes approximately 3 months before symptoms resolve and the athlete is able to return to play. Evidence of radiographic healing typically lags behind the clinical course, and therefore normal radiographs are not necessarily required to allow an athlete to return to activities. During this period of relative rest, physical therapy should also be initiated for strengthening exercises, and if the athlete is a baseball player, evaluation of throwing mechanics and progression through an interval throwing program when the patient is pain-free is also crucial. The most important factor in the management of little league shoulder, however, is education and prevention. One should ensure adherence to youth baseball pitching guidelines set forth by the USA Baseball Medical & Safety Advisory Committee and the American Academy of Pediatrics (AAP) as they pertain to pitch count, pitch types, and adequate rest period.

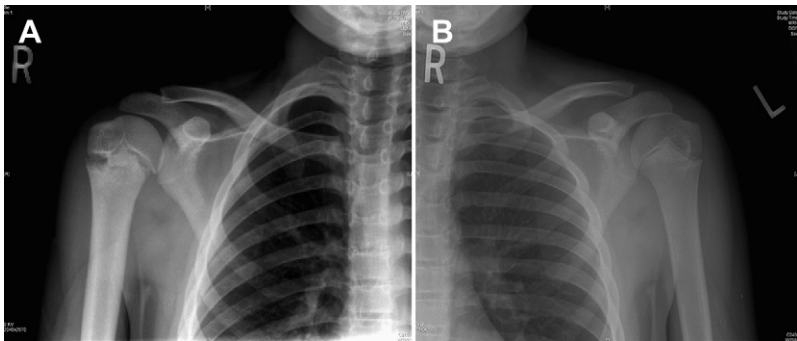


Fig. 1. Radiograph of right shoulder proximal humerus epiphysitis. Notice the widened and sclerotic proximal humerus physis compared with normal left shoulder.

Multidirectional shoulder instability

Shoulder instability in the young athlete can be caused by an acute traumatic injury (shoulder dislocation) or can be atraumatic secondary to underlying capsular laxity. Multidirectional instability (MDI) is a well-known cause of chronic shoulder pain and is generally a bilateral, atraumatic condition affecting shoulder function. MDI refers to laxity within the glenohumeral joint in all planes of motion, leading to hypermobility and decreased stability. It is caused by generalized capsular laxity and insufficiency of the labrum, ligaments, and muscles that stabilize the shoulder joint [9–11].

The presenting symptoms of multidirectional instability often have an insidious onset and are usually associated with increases in duration, frequency, or intensity of overhead activities, such as swimming, baseball, racquet sports, and volleyball [9,12]. Athletes complain of activity-related generalized shoulder pain, usually worse in the dominant arm. Symptoms typically wax and wane with changes in activity level and overhead motions. Patients usually have no history of frank shoulder dislocation, but recurrent shoulder subluxations may be noted even with activities of daily living [9,11–13]. MDI may also present with pain from related conditions, such as shoulder impingement or labral tears.

Examination findings for MDI should be expected in both shoulders. With adequate relaxation, shoulder laxity in multiple planes can be evaluated. The humerus can be passively translated anteriorly and posteriorly, and the classic feature of MDI is demonstration of the sulcus sign. For the sulcus sign, the arm is pulled inferiorly and the presence of a dimple below the acromion signifies the presence of inferior instability. According to early studies by Neer and Foster [14], the combination of posterior and inferior laxity is classic for MDI [9,15,16]. For symptomatic anterior instability, the apprehension test can be applied. With the patient's arm in the abducted and externally rotated position, passive stressing of the shoulder into further external rotation will cause a sensation of the shoulder wanting to dislocate (Fig. 2). This reaction results in patient guarding and apprehension and is considered a positive test. The apprehension test can then be followed by the relocation test, which also tests for symptomatic anterior instability. For this test, the arm is again abducted and externally rotated, but this time with the patient lying supine. While in this position, the arm and humeral head is then pulled forward toward the examiner. This movement will cause pain and apprehension, which can then be relieved by applying posterior force to the shoulder to stabilize it (Fig. 3). If this improves the pain and apprehension, it is considered a positive test.

Workup with imaging is usually not indicated for MDI without associated injury, because MDI is a clinical diagnosis [9,12,15]. Radiographs of the shoulder are usually normal, although inferior and superior translation can be noted and misinterpreted for frank dislocation without knowledge of the patient history. If concern exists about rotator cuff or labral disease, MRI with arthrogram of the shoulder can help identify these lesions.

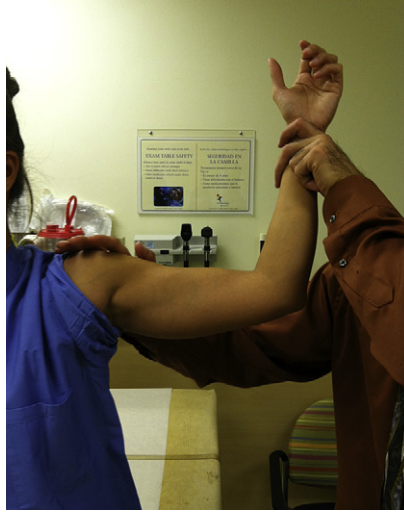

Fig. 2. Apprehension test.

Treatment of MDI without known associated labral or rotator cuff disease is usually conservative, with relative rest from offending activities and physical therapy. After an initial period of rest and antiinflammatories to improve pain, physical therapy should begin with strengthening exercises for the dynamic rotator cuff and scapular stabilizer muscles [9,15,17]. An endurance

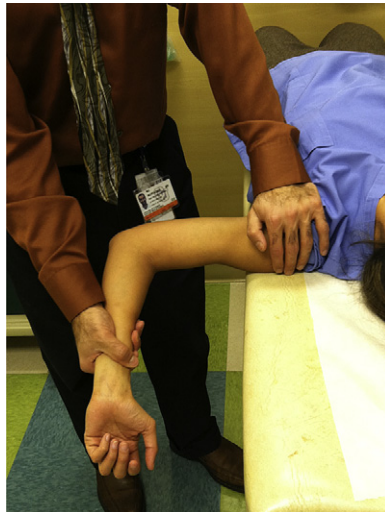

Fig. 3. Relocation test.

program should also be added to strengthening exercises to prevent fatigue-induced injury on return to activities. When the athlete has regained pain-free full strength and range of motion, gradual return to play through increasing sport-specific activities can be initiated.

Medial epicondyle apophysitis (little league elbow)

Little league elbow is intended to refer specifically to medial epicondyle apophysitis. It is a traction injury to the medial epicondylar physis and can be best understood by considering how throwing forces are applied to the medial elbow. Important anatomic considerations of the medial elbow include the medial epicondyle, medial epicondyle apophysis, and ulnar collateral ligament. Injury to this area is caused by repetitive valgus stress to the medial elbow seen in overhead sports [18,19]. Force mechanisms include both compression to the lateral elbow involving the radiocapitellar joint and traction to the medial elbow created by repetitive dynamic valgus stress involved in throwing motions [19,20].

The incidence of medial epicondyle apophysitis is increasing as the numbers and intensity of organized youth sport have increased [21–23]. This condition most commonly presents between 9 and 12 years of age before closure of the medial epicondyle apophysis [18,21,24]. Once the medial epicondylar physis closes, valgus forces are transmitted to other medial elbow structures, and injuries such as flexor-pronator tendonitis or ulnar collateral ligament sprains occur instead. Medial epicondyle apophysitis is most common in baseball pitchers, but is also seen in infielders, catchers, outfielders, and athletes participating in other overhead activities, such as football quarterbacks and tennis players [21–23].

Typically, patients have no history of acute injury. Athletes will complain of insidious onset of medial elbow pain with throwing, but in severe cases pain may also occur with nonthrowing activities. Often athletes report a history of weaker or less-accurate throws. Inquiring about what position they play, the number of teams and seasons per year, throwing history (including pitch count, number of practices and games), and any recent changes in throwing techniques becomes important. Physical examination will reveal tenderness localized over the medial epicondyle, and pain can be reproduced with valgus stressing. Having the patient flex the wrist or pronate the forearm against resistance can also elicit pain. Range of motion may also be limited and strength decreased because of pain.

Workup generally involves imaging that starts with plain radiographs of the elbow. Radiographs are useful for ruling out other abnormalities such as fractures, osteochondral defects, loose bodies, growth plate irregularities, tumors, and infections. In medial epicondyle apophysitis, radiographs are typically normal, but widening of the apophysis and even an avulsion are not uncommon. A comparison view of the opposite elbow may be helpful when clinical suspicion is high, because radiographs show a large degree of variation in normal growth centers. MRI is rarely necessary to confirm the diagnosis.

Treatment of medial epicondyle apophysitis consists of complete throwing restriction and symptom control with ice and antiinflammatories. Based on severity and duration of symptoms, the timeline for recovery will be different for every individual. An initial period of immobilization with a brace or cast may be necessary for the most severe cases in patients experiencing persistent pain at rest. Most will benefit greatly from initiating physical therapy early, and this is highly recommended [18,20,21]. The initial treatment phase involves initiation of range-of-motion exercises and joint mobilizations as necessary to prevent joint contractures. General conditioning is encouraged and core strengthening is usually started right away [18,21]. When tolerated, gradual strengthening is then used. Physical therapy should also address the athlete's throwing mechanics to decrease load forces on the elbow. When athletes are pain-free with full range of motion and near full strength, an interval throwing program should be initiated, which will gradually progress them through stages of increased throwing velocity and repetitions [18,21,22,24]. One critical component of rehabilitation is that return to play is gradual, because potential complications include worsening symptoms, abnormal bone development, or an avulsion injury.

AS with little league shoulder, education and prevention are key in the management of little league elbow. Proper throwing mechanics should be taught and pitching guidelines should be followed. Current AAP recommendations along with those of Little League Baseball specify age-specific maximum pitch counts, required rest days, and recommended pitch types; maximum pitch counts are 50 to 105 pitches per game depending on age [25]. USA Baseball Medical & Safety Advisory Committee recommends no more than 75 to 125 pitches per week depending on age [26].

Gymnast's wrist (distal radius epiphysitis)

Gymnast's wrist is a well-known overuse phenomenon that affects 25% to 40% of all gymnasts, and up to 80% in the most elite groups [27–29]. This injury involves a stress reaction of the distal radius physis and epiphysis and is caused by repetitive forces across the wrist joint, particularly with axial loading of the wrist in hyperextension [30–33]. Other forces experienced at the wrist by gymnasts, such as rotational and distraction forces, also have been noted to play a significant role in causing injury to the distal radius epiphysis [30,34]. Gymnasts are often involved in activities requiring weight-bearing with their wrist in hyperextension, such as the beam, tumbling, vault, and floor routines. These activities create direct axial and rotational forces onto the distal radius physis, which over time results in microtraumatic changes to the epiphysis and the vulnerable cartilaginous growth plate.

Obtaining a sports-specific history is vital, because gymnasts commonly present with recent increases in activity level with wrist-loading routines [28,30,31,35]. A history should be obtained of the athlete's level, hours per week, and types of routines causing the most wrist pain. The most common complaint is wrist pain that begins at the onset of the offending activity,

worsens during the activity, and improves with rest. The physical examination shows tenderness along the radial physis and pain with wrist hyperextension and axial loading [29,30,35], as in the table push-off test, which usually reproduces the wrist pain (Fig. 4).

Decreased range of motion, especially with extension, and swelling are also seen in more advanced cases [30,31,35], and the athlete's grip strength is usually decreased on the symptomatic side.

Radiographs are obtained to evaluate for radiographic evidence of stress injury to the distal radial physis. Comparison views of the unaffected wrist are often very helpful. These radiographic findings include widening, sclerosis, and calcification of the radial physis consistent with repetitive microtrauma [27,30,36]. The origin of these changes has been postulated to occur from blood supply compromise, leading to abnormal endochondral ossification of the physis [30,34,37]. More-advanced disease may lead to radial physis growth arrest and a positive ulnar variance (greater relative length of distal ulna with respect to the distal radius) [30,34,38]. Follow-up radiographs are critical to document healing or progression of physeal injury [30,34,39].

Gymnast's wrist can be separated into three different stages [30,34,39]. Stage one presents with clinical symptoms without any radiographic changes. Stage two exhibits radiographic changes as noted earlier (Fig. 5). Stage 3 has radiographic findings of a positive ulnar variance. MRI of the wrist is usually unnecessary for this diagnosis and is only obtained when other possible abnormality is suspected [30,39].

The mainstay of treatment of gymnast's wrist involves rest from wrist-loading activities. Ice, antiinflammatories, and immobilization in a wrist brace as needed for pain control can be used. Physical therapy is usually helpful and a graded return to activity is essential. Physical therapy during the rest and rehabilitation phase should include focused assessment of limb alignment, laxity, strengthening, and proprioception [28,30]. A wrist brace or taping to reduce wrist

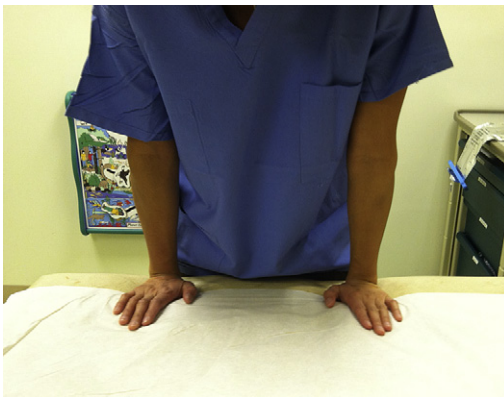

Fig. 4. Table push-off test.

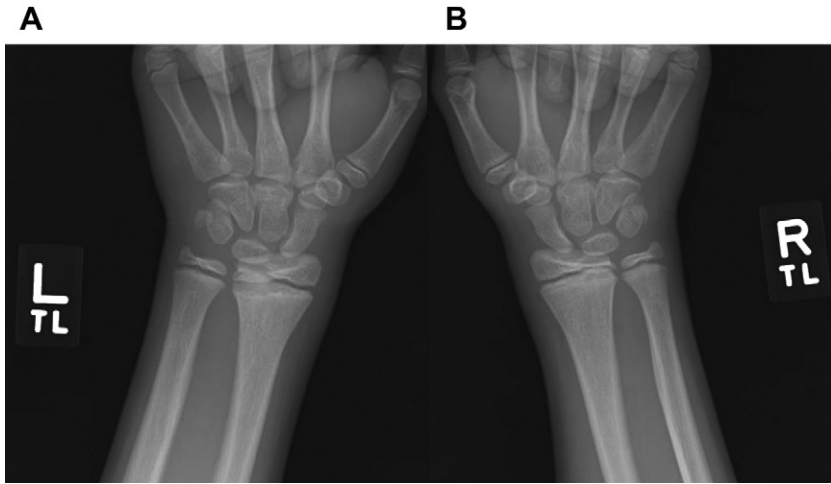


Fig. 5. (A) Left wrist with subtle widening of radial physis and sclerosis through radial metaphysis. (B) Right wrist normal comparison view.

hyperextension on return to gymnastics is often helpful in reducing loads over the radial physis [30]. Gymnasts with stage one injuries can gradually return to activity once pain has resolved, which usually takes 3 to 6 weeks. Stage two injuries may take much longer, sometimes even up to 3 months, to heal, and require both clinical and radiographic confirmation of resolving injury before the patient can return to gymnastics [28,30,37]. Stage three injuries usually will require a period of immobilization with bracing and orthopedic consultation and close follow-up with serial radiographs to assess for premature closure of the distal radial physis [28,30,37]. Participation should be abruptly stopped and the wrist reevaluated on any recurrence of pain.

LOWER EXTREMITY INJURIES

Iselin disease (fifth metatarsal apophysitis)

Iselin disease, first described in 1912 by Dr Iselin, is another chronic overuse injury seen in young athletes that involves the apophysis of the fifth metatarsal [40,41]. It results from repetitive traction on the apophysis at the base of the fifth metatarsal, where the peroneal brevis tendon attaches. The apophysis typically appears at 8 to 9 years of age and fuses between 12 and 15 years of age, making ages 8 to 15 years most common for presentation of Iselin disease [42–44].

Although it occurs with running and jumping activities, Iselin disease is more commonly associated with cutting sports that create inversion stress on the ankle, which requires repetitive activation of the peroneal muscles [44–46]. A history of trauma is usually absent. However, acute inversion injuries have been reported as both initiating and exacerbating events [43,45,46]. Presenting

symptoms include pain and tenderness at the base of the fifth metatarsal. It is typically insidious in onset, aggravated with activity, and gradually worsens over time without rest from activity.

On examination, a prominence of the fifth metatarsal base may be present, sometimes with soft tissue swelling and mild erythema. Focal tenderness is found at the base of the fifth metatarsal, and resisted eversion can illicit pain in this area. Full dorsiflexion and plantar-flexion with inversion also may produce discomfort in the same location. In some patients with longstanding Iselin disease, gait may be altered, with patients attempting to weight-bear on the medial side of the foot to avoid lateral foot pain. Like other apophyseal overuse injuries, Iselin disease is a clinical diagnosis. Radiographs can be obtained to confirm the presence of an apophysis at the base of the fifth metatarsal and to rule out other bony abnormalities. The oblique view of the foot usually produces the best view of a small shell-shaped fleck of bone oblique to the fifth metatarsal shaft (Fig. 6) [43–45]. The apophysis may appear widened, fragmented, and thickened.

Treatment of Iselin disease is centered around activity modification, icing, antiinflammatories, and peroneal stretching and strengthening. For more symptomatic or recalcitrant cases, physical therapy should focus on ankle flexibility, particularly of the evertors and plantar-flexors; ankle strengthening; and proprioceptive exercises [41,43,45,47]. These exercises can improve dynamic ankle stabilization, which can minimize repetitive traction forces on the fifth metatarsal apophysis from ankle instability. With mild to moderate cases, symptoms typically improve with conservative treatment and one can anticipate return to play in 3 to 6 weeks. More severe cases may require an

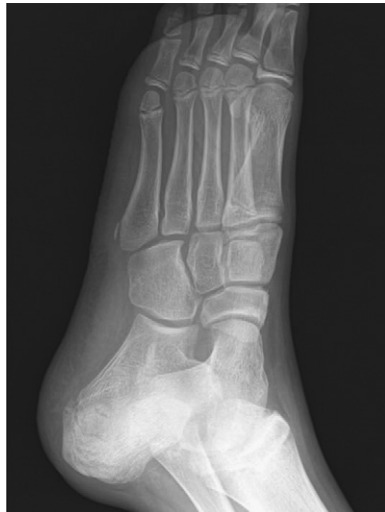

Fig. 6. Fifth metatarsal apophysis.

immobilization period with a walking boot or cast followed by physical therapy for 2 to 4 weeks before return to play [43–46]. In almost all cases, this condition resolves by the time of closure of the apophysis, typically by 15 years of age. Rarely, a nonunion of the apophysis causing symptoms into late adolescence can occur with Iselin disease, which may warrant orthopedic consultation to discuss surgical excision or fixation if conservative treatment fails [41,45,46].

Sever disease (calcaneal apophysitis)

Calcaneal apophysitis, or Sever disease, is the most common cause of heel pain in young athletes and accounts for 8% of all pediatric overuse injuries [42,43]. Sever disease is a chronic traction injury that occurs at the calcaneal apophysis with repetitive tension forces applied by the calf muscles through the Achilles tendon. Radiographically, the calcaneal apophysis appears at 8 to 9 years of age and typically fuses between 12 and 15 years of age (Fig. 7) [48,49].

Calcaneal apophysitis is most commonly seen in athletes participating in sports requiring running, jumping, and plantar-flexion activation. Common sports include soccer, basketball, track, gymnastics, and dance [42,45,48,49].

Athletes present with pain in one or both heels, although bilateral involvement is typical. The most common age group affected is 10 to 12 years of age, with the condition being two to three times more common and occurring 1 to 2 years later in boys because of later skeletal maturity [42,45,49]. Pain is activity-related and reported to be along the heel or at the posterior aspect of the heel where the Achilles tendon inserts onto the apophysis. Patients will often limp or walk on toes to prevent painful walking. Examination reveals tenderness along the calcaneal apophysis, either medial or lateral, and can be elicited through medial and lateral compression of the calcaneus along the apophysis (Fig. 8).

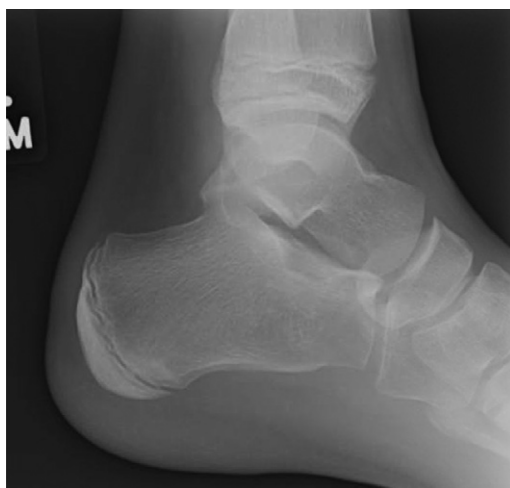

Fig. 7. Calcaneal apophysis.

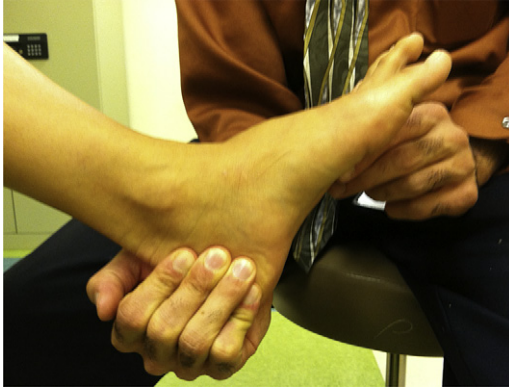

Fig. 8. Calcaneal squeeze test.

Tenderness can also be found at the Achilles insertion site on the calcaneus. Athletes will also often have tight calf muscles and Achilles tendon, with weakness on dorsiflexion because of pain. Radiographs typically appear normal or may reveal a fragmented hyperdense sclerotic apophysis [43,49]. Radiographs of the calcaneus are not necessary to confirm the diagnosis if the history and clinical findings are consistent, but can be obtained to rule out other bony disease. Studies have found that up to 5% of radiographs in patients with heel pain reveal pathologic conditions, making radiographic evaluation worthwhile even in light of a clear clinical picture for Sever disease [50].

Treatment consists of relative rest and activity modification, coupled with ice and antiinflammatories as needed for pain. Rehabilitative exercises focused on calf and Achilles stretching and eccentric strengthening of the Achilles can help decrease traction forces applied to the apophysis. Although high-level evidence supporting the use of orthotics is still lacking, heel cups, lifts, and pads have been reported to reduce traction forces and axial loads on the calcaneal apophysis, helping to decrease symptoms [42,49,51]. When pain and flexibility improve, the athlete may gradually return to sports as symptoms permit, because it is a self-limited process that will resolve when the calcaneal apophysis closes [43,48,49]. More severe symptoms of persistent pain and limping may benefit from a short period of immobilization with a walking boot or casting before gradual return to sports [43,45,49]. With early diagnosis and appropriate treatment, immobilization is rarely required and only reported in 1% to 3% of patients [48]. In fewer than 1% of cases, neglected Sever disease can progress to calcaneal avulsion injury [52].

Osgood-Schlatter disease (tibial tubercle apophysitis)

Osgood-Schlatter disease is a tibial tubercle apophysitis that commonly causes anterior knee pain in children and adolescents. It results from repetitive traction of the patella tendon on the tibial tubercle apophysis, leading to microtrauma,

inflammation, and pain. It frequently presents between the ages of 10 and 15 years in children who participate in jumping and running sports, such as basketball, volleyball, gymnastics, and soccer [53,54]. Approximately 30% of patients have bilateral knee involvement [55,56].

The typical clinical presentation is aching pain and swelling over the tibial tubercle that is exacerbated by jumping and running activities, and with direct pressure such as kneeling. On examination, patients experience point tenderness, and associated swelling or prominence over the tibial tubercle may be present. Resisted knee extension, which activates eccentric quadriceps muscle movement, may also reproduce the pain. Evaluation with radiographs is often not necessary because it is a clinical diagnosis, but these should be obtained to rule out other abnormalities, such as fractures or tumors, if the clinical presentation is atypical. Radiograph findings of Osgood-Schlatter disease include overlying soft tissue swelling and fragmentation or irregularity of the tibial tubercle ossification center.

Management of Osgood-Schlatter disease is conservative, aimed at symptom control. Treatment involves relative rest and activity modification, along with icing and analgesics with nonsteroidal antiinflammatory drugs (NSAIDs). Use of an infrapatellar strap, which helps to decrease traction forces on the tibial tubercle, may be used for symptomatic relief during activity. Physical therapy focusing on quadriceps and hamstring flexibility can also help reduce symptoms.

Osgood-Schlatter disease is typically a self-limited process, with symptoms resolving spontaneously when the child or adolescent reaches skeletal maturity. However, some individuals develop persistent symptoms that remain into adulthood. One retrospective study reported that 60% of patients with childhood Osgood-Schlatter disease described pain with kneeling as adults, although 76% of them did not have any pain or limitations with activity [57]. For the few who experience complications, such as persistent painful ossicles in the distal patellar tendon and painful kneeling, and those for whom conservative management fails, surgical treatment to shave the tibial tubercle can be performed in skeletally mature patients [58,59].

Sinding-Larsen-Johansson disease (apophysitis of the inferior pole of the patella)

Sinding-Larsen-Johansson disease is another common overuse injury that causes anterior knee pain. It is similar to Osgood-Schlatter disease, except that it is a traction apophysitis that occurs at the inferior pole of the patella where the proximal patella tendon attaches. Presentation typically occurs between 9 and 12 years, which is slightly younger than in Osgood-Schlatter disease. Patients present with activity-related anterior knee pain localized to the inferior pole of the patella. Like Osgood-Schlatter disease, symptoms are aggravated by jumping and running. On examination, the pain can be reproduced with direct palpation of the inferior pole of the patella. Diagnosis is made clinically, although radiographs can be helpful to rule out other abnormalities. Radiograph findings may show fragmentation of the distal pole of the patella.

Like Osgood-Schlatter disease, it is a self-limited process that responds well to conservative treatment involving relative rest and activity modification. Pain control with NSAIDs and stretching exercises to improve quadriceps and hamstring flexibility can also improve symptoms.

Patellar tendinopathy ("jumper's knee")

Repetitive loading of the quadriceps muscle during jumping and running activities can lead to patellar tendinopathy, an overuse injury resulting in partial-thickness tears in the deep layers of the patella tendon. Although the condition is seen commonly in jumping sports, such as basketball, volleyball, and track and field (high and long jump), athletes in other sports such as soccer and football are also affected [60,61]. Once thought to be an inflammatory tendinitis, histopathologic and biochemical studies have now shown that it is a degenerative tendinosis. The pathogenesis is tendon overload from strain that is applied to the patella tendon, resulting in tissue microtrauma [62]. Consequently, management of patellar tendinopathy should be aimed at rehabilitation rather than antiinflammatory strategies.

Patients present with insidious onset of anterior knee pain that is aggravated with activity or even with prolonged sitting. Generally, these patients have a history of recent increase in intensity, frequency, or duration of sport activity participation. The pain is well localized and examination reveals tenderness over the patellar tendon. Although primarily a clinical diagnosis, radiographs may sometimes reveal calcification in the tendon, and they can also be helpful to rule out other associated conditions such as Osgood-Schlatter or Sinding-Larsen-Johansson disease. Ultrasound has also become a popular imaging modality for diagnosis because the patella tendon lies superficial and can be visualized easily.

Because patellar tendinopathy is an overuse injury from mechanical overload, treatment includes relative rest and refraining from the aggravating activities while still symptomatic. The role of NSAIDs remains controversial, because patellar tendinopathy is a noninflammatory condition. The literature contains no conclusive evidence showing that NSAIDs have an effect on the treatment outcome of patellar tendinopathy [63], although patients with acute pain may benefit from the analgesic effects. Conservative management through physical therapy remains the mainstay of treatment. Although scientific evidence on the efficiency of nonoperative treatment is still lacking, management of patellar tendinopathy continues to focus largely on eccentric strengthening of the tendon [64]. Improving quadriceps and hamstring flexibility can also be beneficial in prevention and treatment of patellar tendinopathy [65]. In some patients for whom conservative management fails after 6 months of therapy, surgical options can be explored.

Patellofemoral pain syndrome

Patellofemoral pain syndrome refers to anterior knee pain originating from the patellofemoral joint and the surrounding supporting structures. It is the most common cause of all knee overuse injuries. Other terms that have been used

to refer to this condition include *anterior knee pain*, *runner's knee*, and *chondromalacia patella*. The cause of patellofemoral pain is multifactorial and includes biomechanical problems, dysfunction of muscles, and overuse. Anatomically, the patella articulates with the trochlear groove of the femoral condyles in the distal femur. Proper tracking of the patella in this groove is dependent on multiple forces such as strength of the quadriceps muscles, supporting soft tissue structures, patellar stabilizing mechanisms, and biomechanics of the patient. Biomechanical problems include lower extremity malalignment, patellar hypermobility, strength imbalances, and muscle inflexibility. Examples of malalignment of the lower extremity include femoral anteversion, genu valgum, excessive lateral insertion of the patellar tendon (increased Q angle), tibial torsion, and foot hyperpronation from pes planus (flat feet). Increases in activities and these predisposing factors causes overload stress on the patellofemoral joint. The result is pain.

Patients complain of a dull aching pain underneath or around the patella that occurs with activity. Prolonged sitting or going up and down stairs typically also aggravates the pain. Mild swelling or a sense of crepitation may also be reported. Symptoms are commonly bilateral, although presentation in one knee is not unusual. Physical examination requires assessment from hips to feet, because malalignment problems can contribute to patellofemoral pain. Abnormal tracking of the patella can be evaluated by extending the patient's knee while in the seated position. If abrupt or excessive lateral tracking of the patella occurs as the knee extends, this is considered positive J tracking. On palpation, tenderness may be present under the patellar facets. Compressing down on the patient's patella while displacing it inferiorly can also elicit pain as the patient is asked to contract the quadriceps; this is a positive patellar grind test (Fig. 9).

Functional deficiencies such as core and pelvic weakness, quadriceps and hamstring tightness, and IT band tightness should also be assessed. Radiographs are not necessary for diagnosing patellofemoral pain, but they can

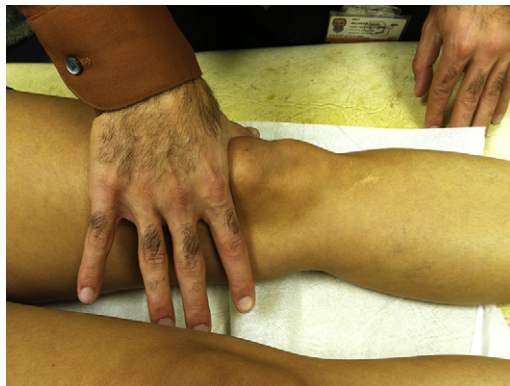

Fig. 9. Patellar grind test.

help confirm abnormalities in patellar alignment (ie, patella alta, femoral trochlea hypoplasia, lateral patella tilt) or rule out other bony abnormalities.

Like many overuse injuries, relative rest and modifying activities based on subjective pain is part of the treatment. Because the origin of patellofemoral pain is multifactorial, management should also address the various predisposing factors, with correction of biomechanical problems being the primary focus. Physical therapy for core and hip strengthening has thus become a mainstay of treatment for this condition. Part of the rehabilitation also addresses any strength imbalances, hamstring and quadriceps inflexibility, and IT band tightness. Use of over-the-counter or customized orthotics may be necessary to correct hyperpronation from pes planus. Patellar stabilizing braces can also be helpful to minimize patellar hypermobility and lateral tracking. For patients who do not respond to conservative management, consultation with an orthopedic surgeon for consideration of a lateral release or patellar realignment surgery is reasonable, although no evidence shows that surgical intervention is effective.

HIP INJURIES

Pelvic apophysitis

Pediatric overuse injuries commonly involve the pelvis during times of rapid growth when bone growth exceeds muscle ability to stretch sufficiently, leading to increased inflexibility and traction forces on the pelvic apophyses. Knowledge of the bony anatomy, muscular attachments, and its actions are key for understanding and diagnosing pelvic apophysitis.

The pelvis has multiple apophyses that may be involved in overuse injuries depending on the type of activity and age, because these secondary ossification centers appear and close at different ages (Table 1).

Table 1
Pelvic apophyses- muscle attachments and ages at time of their ossification

Apophysis	Originating muscle	Inserting muscle	Age of appearance (y)	Age of closure (y)
Greater trochanter	None	Gluteus maximus and medius, external hip rotators	9–10	14–16
Lesser trochanter	None	Iliopsoas	9–10	14–16
Anterior superior iliac spine	Sartorius	None	12–14	14–16
Anterior inferior iliac spine	Rectus femoris	None	12–14	14–16
Iliac crest	Tensor fascia latae	Internal and external obliques, transversus abdominis	13–15	16–18
Ischial tuberosity	Biceps femoris, hip extensors	None	15–17	21–25

The muscles originating or attaching at each apophysis create traction forces with activity as the muscle-tendon group repetitively pulls against the apophysis, producing microavulsion, inflammation, and cellular breakdown [66–68]. Eventually the cartilaginous apophysis weakens and leads to widening of the apophysis, putting the athlete at high risk for an acute avulsion injury [49,69–71]. The most commonly injured apophyses of the pelvis include the ischial tuberosity, anterior inferior iliac spine (AIIS), and anterior superior iliac spine (ASIS), followed less commonly by the lesser trochanter, iliac crest, and rarely the greater trochanter [67,69]. The actions of the muscles involved at the injured apophysis are often repetitive motions common to specific types of sports. For example, sprinters will often experience ischial tuberosity apophysitis from recurrent ballistic hamstring use during explosive sprints, and figure skaters will experience iliac apophysitis from explosive jumping and twisting that engages their oblique muscles. Pelvic apophysitis occurs commonly in a variety of sports, including soccer, running, gymnastics, skating, football, and dance, but may occur in any sport [49,66,67].

Athletes present with well-localized activity-related pain at the site of the involved apophysis. In contrast to acute avulsion injuries, the athlete's pain is insidious in nature and is usually described as aching or throbbing. Without appropriate rest, the pain will progress and athletes may develop limp with activities and pain with walking or standing. With continued activity despite worsening pain, athletes are at risk for avulsion fracture at the apophysis, and may describe a sudden painful event in which a pop is felt followed by intense pain and disability of the involved muscle [42,49,68,70,71].

Physical examination will reveal significant localized pain directly over the involved apophysis on palpation. Some local swelling may be present, but erythema, bruising, and deformity are usually not appreciated unless an avulsion fracture has occurred. The pain is worsened by resisted activation or passive stretching of the involved muscle group. Muscle tightness is often appreciated bilaterally, and range of motion is usually decreased on the affected side. With more advanced apophysitis, mild contractures may be noted.

Workup involves radiographs of the pelvis and hip to visualize the apophysis of concern. However, radiographs typically appear normal, making this a clinical diagnosis. In moderate to severe cases, radiographs may show an apophysis with widening and sclerosis. Radiographs should be obtained in the presence of concerns for constitutional symptoms, tumors, infection, or persistent symptoms not responding to therapy. Avulsion fractures should be ruled out with radiographs if the history is concerning for such. On MRI, edema of the apophysis can be appreciated in its early stages before widening and sclerosis [69–71]. However, MRI is unnecessary for the diagnosis and should only be obtained when other concerns exist, such as infections, tumors, or stress fractures.

The mainstay of treatment for pelvic apophysitis is rest and activity modification to prevent further injury from the insulting activity. Ice and ibuprofen can be used for pain as needed. Weight-bearing is allowed as tolerated. However, protected weight-bearing on crutches may be necessary initially if the athlete has

pain with walking and standing. If needed, physical therapy can usually be initiated by 1 to 2 weeks, with a focus on flexibility and range of motion, and progressing to core and pelvic strengthening and lower extremity strengthening. When symptom-free, it is important to engage the athlete in a graded return to sports-specific activities before full participation. In general, most can expect to return to full participation at 4 to 6 weeks [49,68].

IT band syndrome (IT band tendinitis)

IT band syndrome is a very common cause of lateral hip pain and lateral knee pain, and is found especially in runners. Anatomically, the IT band is a large connective tissue structure that runs from the iliac crest down to the lateral tibia. With hip flexion and extension, the IT band glides anteriorly over the greater trochanter in the femur and then glides back posterior to the trochanter, respectively. The friction that is created by the IT band sliding back and forth results in pain. A trochanteric bursa allows for smooth gliding of the IT band through reducing friction, but when this bursa becomes inflamed, an associated trochanteric bursitis can also develop, resulting in painful movement. Running downhill causes the worst pain because symptoms typically occur when the hip is flexed at 30°. This reduced foot strike angle on downhill running is a risk factor for developing IT band syndrome, because track athletes who run on level surfaces, and thus have greater foot strike angle, have been found to have a lower incidence of this condition.

Clinically, patients present with achy pain over the lateral upper thigh and knee with running. On examination, they may have tenderness over the greater trochanter if a bursitis has developed, or they may have tenderness in the knee over the lateral femoral condyle. Symptomatic patients generally have findings of a tight IT band on examination, as indicated by a positive Ober test. For this test, the patient is in a side-lying position, with the affected side up. The examiner then extends the symptomatic hip while supporting the leg. With IT band inflexibility, the knee and leg will remain suspended off the table once the examiner no longer supports the leg up (Fig. 10).

Physical examination also will often reveal biomechanical abnormalities. Varus alignment of the lower extremity (bowlegged), overpronation from high arches, or lateral tilt of the pelvis can all place strain on the IT band, predisposing individuals to this condition [72].

Treatment aims at reducing stress on the IT band, both through physical therapy and correction of any biomechanical problems. In addition to stretching the IT band and hamstrings to decrease friction, physical therapy should also strengthen gluteal and hip abductors to minimize pelvic tilt. Ice and NSAIDs for symptomatic control can be helpful. More importantly, addressing training errors, such as excessive downhill running or rapid increases in activity, can help prevent recurrences. For those who fail conservative management, consultation with a surgeon for surgical release of the IT band is an option. Most athletes are generally able to gradually return to sport activities within 2 to 6 weeks once they are asymptomatic [73].

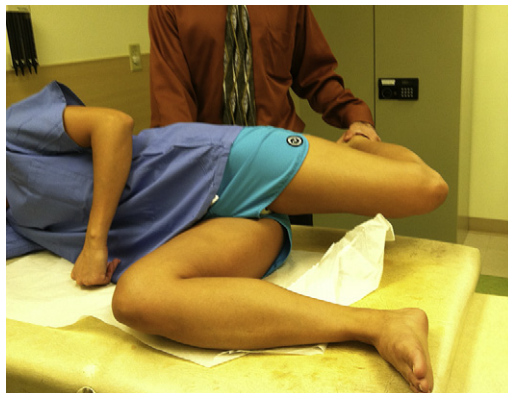

Fig. 10. Ober test.

BACK INJURIES

Spondylolysis

Spondylolysis is a stress fracture of the pars interarticularis, the bony connection between the inferior and superior articulating facets of the vertebral complex. Estimates show that spondylolysis may contribute to nearly 50% of cases of back pain in young athletes, and physicians should always maintain a high index of suspicion for this diagnosis [53]. The cause of the defect in the pars interarticularis is stress to the posterior elements of the spine from repetitive flexion and hyperextension motion, combined with truncal rotation. Gymnastics, football (lineman), weight lifting, dance, and volleyball are common sports requiring repetitive hyperextension that may lead to spondylolysis [3,53]. The stress fracture occurs most commonly at the L5 vertebral level, followed by the L4 level [74–76], and can be unilateral or bilateral. If the stress fracture at the pars interarticularis occurs bilaterally, then spondylolisthesis can develop, which is a forward slippage of one vertebral body on the vertebral body below it. Diagnosis and grading of spondylolisthesis can be made on lateral radiographs based on percentage of anterior displacement.

Patients with spondylolysis typically present with insidious onset of activity-related low back pain that worsens with spine hyperextension. The prototypical patient falls into one of three categories: (1) the female athlete with a hyperlordotic spine with increased motion and flexibility, (2) the male athlete with poor flexibility, particularly of the paraspinal musculature, and who has recently undergone a growth spurt, and (3) the deconditioned athlete with poor core and pelvic strength who recently started a new sport. On physical examination tenderness to palpation may be present at the affected vertebral level. Findings may also show increased lordosis of the lumbar spine, poor hamstring flexibility, and weak core and pelvic strength. The pain is reproducible when the patient extends the back or with single-leg hyperextension during the Stork test (Fig. 11).

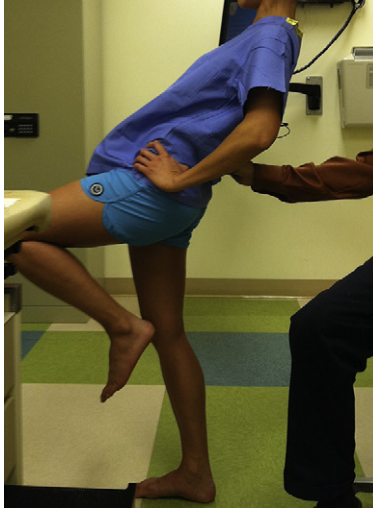

Fig. 11. Stork test.

Diagnostic workup should begin with plain radiographs, including antero-posterior and lateral views of the lumbar spine. Obtaining oblique views to look for the “Scotty dog” sign in the pediatric patient remains debatable because of the increase in radiation exposure and uncertainty regarding whether it improves diagnostic accuracy. In general, plain radiographs have been shown to have poor sensitivity in demonstrating pars defects [77] but can be helpful to assess for other gross bony abnormalities.

Further imaging with single-photon emission CT (SPECT) scan, CT scan, and/or MRI is generally necessary to confirm the diagnosis. Which imaging modality is most sensitive and specific for detecting a pars stress fracture remains controversial. Each has its own advantages and disadvantages. The SPECT scan has increased sensitivity of up to 68% over radiographs [78,79] and can be helpful in distinguishing symptomatic pars stress fractures from asymptomatic lesions based on whether increased uptake is seen on the scan. However, it has poor specificity and cannot rule out other pathologies that also demonstrate increased uptake, such as infections or tumors. CT, on the other hand, provides excellent visualization of bony anatomy and can identify the exact location of the stress fracture. It can also be used on follow-up to assess bony healing. The downfall is the amount of radiation exposure. More recently, use of MRI for diagnosing spondylolysis has become more popular because of the lack of radiation exposure in pediatric patients and the ability to detect bone marrow edema (stress reaction) and soft tissues. With improvements in magnetic field and strength and fat saturation techniques, high-resolution MRI images have increased diagnostic accuracy. However, the efficacy is still being studied [80–83].

No gold standard for management of spondylolysis currently exists. Its clinical outcome has little correlation with radiographic evidence of healing status [84]. That is, patients with healed stress fractures or with bony nonunions can be asymptomatic. Thus, treatment consists primarily of a period of high-impact and extension-based activity restrictions to alleviate pain and allow for bony healing and/or progression to fibrous nonunion. No universal guideline exists for the duration of activity restriction, although most authors would agree that a period of relative rest of approximately 3 months is reasonable. During this time physical therapy is started once pain is improved, with rehabilitation emphasizing core and back stabilization and hamstring flexibility. The use of bracing in the treatment of spondylolysis remains controversial; some still advocate for bracing until the patient is asymptomatic, which may take up to 9 to 12 months [53,85]. Outcome studies show similar results with return to sports and bony healing regardless of whether bracing was used. Given the lack of evidence supporting therapeutic bracing, many will reserve bracing for severe cases in which pain is experienced at rest and with daily activities. Most patients with symptomatic spondylolysis respond well to nonoperative management. Once symptom-free, the athlete may gradually return to sport activities without restrictions. For recalcitrant cases for which conservative measures fail after 9 to 12 months, surgical options may be considered, with posterolateral fusion having a success rate of close to 90% [84].

SUMMARY

Overuse injuries in the pediatric and adolescent population are a growing problem in the United States as more children participate in recreational and organized sports. It is not uncommon for children and adolescents to play on multiple teams simultaneously or to be involved in sports year-round. Without adequate rest, the demands of exercise can exceed the body's ability to repair tissues, leading to repetitive microtrauma and overuse injury. Unlike in adults, the consequences of overuse injury in the pediatric and adolescent athlete are far more serious because the growing bones are vulnerable to stress. The ability to identify individuals who are at risk of overuse injuries is key so that education, prevention, and early diagnosis and treatment can occur. Preventive measures of modifying training factors (ie, magnitude, intensity, and frequency of sports participation) and correcting improper biomechanics (alignment, laxity, inflexibility, and muscle imbalance) should always be part of the management plan.

References

- [1] Adirim TA, Cheng TL. Overview of injuries in the young athlete. *Sports Med* 2003;33:75-81.
- [2] Bennell KL, Brukner PD. Epidemiology and site specificity of stress fractures. *Clin Sports Med* 1997;16:179-96.
- [3] Micheli LJ. Overuse injuries in children's sports: the growth factor. *Orthop Clin North Am* 1983;14(2):337-60.

- [4] Kocher MS, Waters PM, Micheli LJ. Upper extremity injuries in the paediatric athlete. *Sports Med* 2000;30:117–35.
- [5] Tullos HS, Fain RH. Little league shoulder: rotational stress fracture of proximal epiphysis. *J Sports Med* 1974;2:152–3.
- [6] Kibler WB, Safran MR. Musculoskeletal injuries in the young tennis player. *Clin Sports Med* 2000;19(4):781–92.
- [7] Patel DR, Nelson TL. Sports injuries in adolescents. *Med Clin North Am* 2000;84:983–1007.
- [8] Carson WG Jr, Gasser SI. Little leaguer's shoulder. A reports of 23 cases. *Am J Sports Med* 1998;26:575–80.
- [9] Castagna A, Nordenson U, Garofalo R, et al. Minor shoulder instability. *Arthroscopy* 2007;23(2):211–5.
- [10] Matsen FA III, Lippitt SB, Sidles JA, et al, editors. Practical evaluation and management of the shoulder. Philadelphia: WB Saunders; 1994. p. 60–81.
- [11] Ovesen J, Nielsen S. Anterior and posterior shoulder instability. A cadaver study. *Acta Orthop Scand* 1986;57(4):324–7.
- [12] Brems JJ, Bergfeld J. Multidirectional shoulder instability. *Orthop Trans* 1991;15:84.
- [13] Owens BD, Duffey ML, Nelson BJ, et al. The incidence and characteristics of shoulder instability at the United States Military Academy. *Am J Sports Med* 2007;35(7):1168–73.
- [14] Neer CS, Foster CR. Inferior capsular shift for involuntary inferior and multidirectional instability of the shoulder. A preliminary report. *J Bone Joint Surg Am* 1980;62(6):897–908.
- [15] Wnorowski DC, Keenan MA. Multidirectional Glenohumeral Instability. Available at: <http://emedicine.medscape.com/article/1262368-overview>. Accessed November 21, 2011.
- [16] Turkel SJ, Panio MW, Marshall JL, et al. Stabilizing mechanisms preventing anterior dislocation of the glenohumeral joint. *J Bone Joint Surg Am* 1981;63(8):1208–17.
- [17] Mahaffey BL, Smith PA. Shoulder Instability in Young Athletes. *Am Fam Physician* 1999;59(10):2773–82.
- [18] Cassas KJ, Cassettari AW. Childhood and adolescent sports-related overuse injuries. *Am Fam Physician* 2006;73(6):1014–22.
- [19] Whiteside JA, Andrews JR, Fleisig GS. Elbow injuries in young baseball players. *Phys Sportmed* 1999;27(6):87–102.
- [20] Andrish JT. Osteochondritis dissecans in a young pitcher: why early recognition matters. *Phys Sportmed* 1997;25:85–90.
- [21] Benjamin HJ, Briner WW Jr. Little league elbow. *Clin J Sport Med* 2005;15(1):37–40.
- [22] Cain EL Jr, Dugas JR, Wolf RS, et al. Elbow injuries in throwing athletes: a current concepts review. *Am J Sports Med* 2003;31:621–35.
- [23] Christopher NC, Congeni J. Overuse injuries in the pediatric athlete: evaluation, initial management, and strategies for prevention. *Clin Pediatr Emerg Med* 2002;3:118–28.
- [24] Lyman S, Fleisig GS, Andrews JR, et al. Effect of pitch type, pitch count, and pitching mechanics on risk of elbow and shoulder pain in youth baseball pitchers. *Am J Sports Med* 2002;30:463–8.
- [25] Protecting Young Pitching Arms. Little League Web site. Available at: http://www.littleleague.org/Assets/old_assets/media/pitch_count_publication_2008.pdf. Accessed December 2, 2011.
- [26] USA Baseball Medical & Safety Advisory Committee Guidelines. American Sports Medicine Institute Web site. Available at: <http://www.asmi.org/asmiweb/usabaseball.htm>. Accessed December 2, 2011.
- [27] Gaine D, Roy S, Singer KM, et al. Stress changes of the distal radial growth plate, A radiographic survey and review of the literature. *Am J Sports Med* 1992;20:290–8.
- [28] Mandelbaum BR, Bartolozzi AR, Davis CA, et al. Wrist pain syndrome in the gymnast: pathogenetic, diagnostic, and therapeutic considerations. *Am J Sports Med* 1986;17:305–17.

- [29] Dobyns JH, Gahcl GT. Gymnast's wrist. *Hand* 1990;6:493–505.
- [30] DiFiori JP, Puffer JC, Mandelbaum BR, et al. Factors associated with wrist pain in the young gymnast. *Am J Sports Med* 1996;24:9–14.
- [31] Webb BG, Retigg LA. Gymnastic wrist injuries. *GUTT. Sports Med Rep* 2008;7(5):289–95.
- [32] Koh TJ, Grabiner MD, Weiker GG. Technique and ground reaction forces in the back hand spring. *Am J Sports Med* 1997;20:61–6.
- [33] Markoff JL, Shapiro MS, Mandelbaum BR, et al. Wrist loading patterns during pommel horse exercises. *J Biomech* 1990;23:1001–11.
- [34] DiFiori JP, Caine DJ, Malina RM. Wrist pain, distal radial physeal injury, and ulnar variance in the young gymnast. *Am J Sports Med* 2006;34:840–9.
- [35] Mitchell JA, Adams BD. Hand and wrist injuries: wrist pain in gymnasts. In: Renstrom PAFH, editor. *Clinical Practice of Sports Injury Prevention Care. The Encyclopedia of Sports Medicine*, vol. 5. Boston: Blackwell Scientific Publications; 1993. p. 78–85.
- [36] Roy S, Caine D, Singer K. Stress changes of the distal radial epiphysis in young gymnasts: a report of twenty-one cases and a review of the literature. *Am J Sports Med* 1985;13:301–8.
- [37] Gabel GT. Gymnastic wrist injuries. *J Sports Med* 1998;17:611–21.
- [38] DiFiori JP, Puffer JC, Dorey AF. Ulnar variance in young gymnasts: a three-year study. *Med Sci Sports Exerc* 2001;33:S223.
- [39] Rettig AC. Athletic injuries of the wrist and hand: part II: overuse injuries of the wrist and traumatic injuries of the hand. *Am J Sports Med* 2004;32:262–73.
- [40] Iselin H. Wachstumbeschwerden zur zeit der knockern entwicklung metatarsi quinti. *Deut Z Chir* 1912;117:529 [in German].
- [41] Lehman RC, Gregg JR, Torg E. Iselin's disease. *Am J Sports Med* 1986;14:494–6.
- [42] Stricker PR, Wasilewski C. Apophysitis. In: Puffer JC, editor. *20 Common problems in sports medicine*. New York: McGraw-Hill; 2002. p. 353–66.
- [43] Gillespie H. Osteochondroses and apophyseal injuries of the foot in the young athlete. *Curr Sports Med Rep* 2010;9(5):265–8.
- [44] Canale ST, Richardson DR. Osteochondroses and related problems of the foot and ankle. In: DeLee JC, Drez D Jr, Miller MD, editors. *DeLee and Drez's Orthopaedic Sports Medicine. Principles and Practice*. 3rd edition. Philadelphia: Saunders Elsevier; 2010.
- [45] Frush TJ, Lindenfeld TN. Peri-epiphyseal and overuse injuries in adolescent athletes. *Sports Health* 2009;1(3):201–11.
- [46] Canale TS, Williams KD. Iselin's disease. *J Pediatr Orthop* 1992;12(1):90–3.
- [47] Schwartz B, Jay RM, Schoenhaus HD. Apophysitis of the fifth metatarsal base. *J Am Podiatr Med Assoc* 1991;81:128–30.
- [48] Weiner DS. Calcaneal apophysitis: simple diagnosis, simpler treatment. *J Fam Pract* 2007;56(5):352–5.
- [49] Wilson JC, Rodenburg RE. Apophysitis of the lower extremities. *Contemp Pediatr* 2011;28(6):38–46.
- [50] Rachel JN, Williams JB, Sawyer JR, et al. Is radiographic evaluation necessary in children with a clinical diagnosis of calcaneal apophysitis (sever disease)? *J Pediatr Orthop* 2011;31(5):548–50.
- [51] Orava S, Virtanen K. Osteochondroses in athletes. *Br J Sports Med* 1982;16:161–8.
- [52] Lee KT, Young KW, Park YU, et al. Neglected Sever's disease as a cause of calcaneal apophyseal avulsion fracture: case report. *Foot Ankle Int* 2010;31(8):725–8.
- [53] Cassas KJ, Cassettari-Wayhs A. Childhood and adolescent sports-related overuse injuries. *Am Fam Physician* 2006;73(6):1014–22.
- [54] Hogan KA, Gross RH. Overuse injuries in pediatric athletes. *Orthop Clin North Am* 2003;34:405–15.
- [55] Wall EJ. Osgood-Schlatter disease: practical treatment for a self-limited condition. *Phys Sportmed* 1998;26:29–34.
- [56] Bloom OJ, Mackler L, Barbee J. Clinical inquiries. What is the best treatment for Osgood-Schlatter disease? *J Fam Pract* 2004;53:153–6.

- [57] Krause BL, Williams JP, Catterall A. Natural history of Osgood-Schlatter disease. *J Pediatr Orthop* 1990;10(1):65–8.
- [58] Weiss JM, Jordan SS, Andersen JS, et al. Surgical treatment of unresolved Osgood-Schlatter disease: ossicle resection with tibial tubercleplasty. *J Pediatr Orthop* 2007;27(7):844–7.
- [59] Flowers MJ, Bhadreshwar DR. Tibial tuberosity excision for symptomatic Osgood-Schlatter disease. *J Pediatr Orthop* 1995;15(3):292–7.
- [60] Blazina ME, Kerlan RK, Jobe FW, et al. Jumper's knee. *Orthop Clin North Am* 1973;4:665–78.
- [61] Ferreti A, Ippolito E, Mariani P, et al. Jumper's knee. *Am J Sports Med* 1983;11:58–62.
- [62] Leadbetter WB. Cell-matrix response in tendon injury. *Clin Sports Med* 1992;11:533–78.
- [63] Almekinders LC, Temple JD. Etiology, diagnosis, and treatment of tendinosis: an analysis of the literature. *Med Sci Sports Exerc* 1998;30:1183–90.
- [64] Peers K, Lysens R. Patellar tendinopathy in athletes. Current diagnostic and therapeutic recommendations. *Sports Med* 2005;35(1):71–87.
- [65] Witvrouw E, Bellemans J, Lysens R, et al. Intrinsic factors for the development of patellar tendinitis in an athletic population: a two year prospective study. *Am J Sports Med* 2001;29:190–5.
- [66] Peck DM. Apophyseal injuries in the young athlete. *Am Fam Physician* 1995;51(8):1891–8.
- [67] Kocher MS, Tucker R. Pediatric athlete hip disorders. *Clin Sports Med* 2006;25(2):241–53.
- [68] Sopano JV. Common overuse injuries in the pediatric and adolescent athlete. *Clin Pediatr Emerg Med* 2007;8(1):7–14.
- [69] Ferbach SK, Wilkinson RH. Avulsion injuries of the pelvis and proximal femur. *AJR Am J Roentgenol* 1981;137:581–4.
- [70] Metzmaker JN, Pappas AM. Avulsion fractures of the pelvis. *Am J Sports Med* 1985;13(5):349–58.
- [71] Pointinger H, Munk P, Poeschl GP. Avulsion fracture of the anterior superior iliac spine following apophysitis. *Br J Sports Med* 2003;37(4):361–2.
- [72] Glazer JL, Hosey RG. Soft-tissue injuries of the lower extremity. *Prim Care* 2004;31(4):1005–24.
- [73] Farber AJ, Wilckens JH, Jarvis CG. Pelvic pain in the athlete. In: Seidenberg PH, Beutler AI, editors. *The sports medicine resource manual*. Philadelphia: Saunders, Elsevier; 2008. p. 317.
- [74] Cavalier R, Herman MJ, Cheung EV, et al. Spondylolysis and spondylolisthesis in children and adolescents. I: diagnosis, natural history, and nonsurgical management. *J Am Acad Orthop Surg* 2006;14:417–24.
- [75] Lawrence JP, Greene HS, Graeur JN. Back pain in athletes. *J Am Acad Orthop Surg* 2006;14:726–35.
- [76] Jones GT, Macfarlane GJ. Epidemiology of low back pain in children and adolescents. *Arch Dis Child* 2005;90:312–6.
- [77] Ward CV, Latimer B, Alander DH, et al. Radiographic assessment of lumbar facet distance spacing and spondylolysis. *Spine* 2007;32:E85–8.
- [78] Collier BD, Johnson RP, Carrera GF, et al. Painful spondylolysis and spondylolisthesis studied by radiology and single photon emission computed tomography. *Radiology* 1985;154:207–11.
- [79] Bellah RD, Summerville MD, Treves ST, et al. Low back pain in adolescent athletes: detection of stress injury to the pars interarticularis with SPECT. *Radiology* 1991;180:509–12.
- [80] Bhatia NN, Chow G, Timon SJ, et al. Diagnostic modalities for the evaluation of pediatric back pain: a prospective study. *J Pediatr Orthop* 2008;28:230–3.
- [81] Standaert CJ, Herring SA. Expert opinion and controversies in sports and musculoskeletal medicine: the diagnosis and treatment of spondylolysis in adolescent athletes. *Arch Phys Med Rehabil* 2007;88:537–40.

- [82] Hollenberg GM, Beattie PF, Meyers SP, et al. Stress reactions of the lumbar pars interarticularis: the development of new MRI classification criteria. *Spine* 2002;27:181–6.
- [83] Udeshi U, Reeves D. Routine thin slice MRI effectively demonstrates the lumbar pars interarticularis. *Clin Radiol* 1999;54:615–9.
- [84] Kim HJ, Green DW. Spondylolysis in the adolescent athlete. *Curr Opin Pediatr* 2011;23:68–72.
- [85] Solomon R, Brown T, Gerbino PG, et al. The young dancer. *Clin Sports Med* 2000;19:717–39.