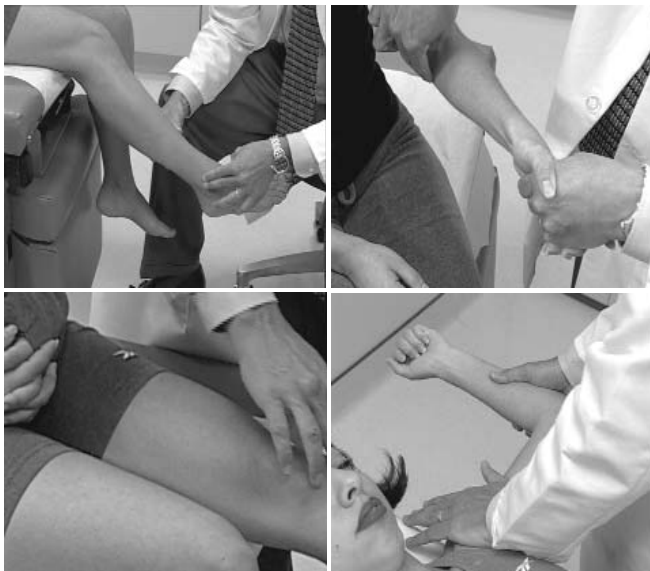

Examination Skills of the Musculoskeletal System

Self-study Program

Author:

Robert Sallis, MD, FAAFP, FACSM
Department of Family Medicine
Kaiser Permanente Medical Center
Fontana, California



American Academy
of Family Physicians

Table of Contents

Disclaimer	3
Author Disclosure	3
About the Author	3
Contributors	4
CME Credit Information	4
Objectives	5
Introduction	6
Shoulder and Neck Evaluation	7
Shoulder and Neck Exam Landmarks	16
Shoulder and Neck Exam Essentials	17
Elbow Evaluation	19
Elbow Exam Landmarks	26
Elbow Exam Essentials	27
Wrist and Hand Evaluation	29
Wrist and Hand Exam Landmarks	37
Wrist and Hand Exam Essentials	38
Lower Back Evaluation	39
Lower Back Exam Landmarks	45
Lower Back Exam Essentials	46
Hip Evaluation	47
Hip Exam Landmarks	54
Hip Exam Essentials	55
Knee Evaluation	57
Knee Exam Landmarks	66
Knee Exam Essentials	67
Ankle Evaluation	69
Ankle Exam Landmarks	76
Ankle Exam Essentials	77
References	79
Acknowledgements	79
Self-assessment Questions	79

DISCLAIMER

The material presented in this program is being made available by the American Academy of Family Physicians for educational purposes only. This material is not intended to represent the only, nor necessarily best, methods or procedures appropriate for the medical situations discussed, but rather is intended to present an approach, view, statement or opinion of the faculty that may be helpful to others who face similar situations.

Physicians may choose to check specific details such as drug doses and contraindications, etc., in standard sources prior to clinical application. Every effort has been made to assure the accuracy of the data presented in this program.

This program should be used as an educational tool to help learn the procedures involved in the examination of the musculoskeletal system. In addition to this program, attendance at a formal course related to these skills and supervised clinical experience is highly recommended.

AUTHOR DISCLOSURE

The AAFP has selected and provides funding for all authors of this syllabus. According to AAFP policy, all relationships between speakers and proprietary entities will be disclosed.

The following author has returned a disclosure form indicating the following:

Robert Sallis, M.D. – Member, Sports Medicine Review Board,
Gatorade Sports Science Institute

The above author has declared that the content of his presentation will not include discussion of unapproved or investigational uses of products or devices.

ABOUT THE AUTHOR

Robert Sallis, MD, FAAFP, FACSM serves as Co-director of the Sports Medicine Fellowship at Kaiser Permanente Medical Center in Fontana, Calif., and as head Team Physician for Pomona College. He is an Assistant Clinical Professor of Family Medicine at the UCR/UCLA Biomedical Sciences Program in Riverside, Calif., and is a Fellow of both the American Academy of Family Physicians and the American College of Sports Medicine. He currently serves as Vice President of the American College of Sports Medicine, and is the Editor-in-Chief of *Current Sports Medicine Reports* and Associate Editor-in-Chief of *Medicine & Science in Sports & Exercise*.

CONTRIBUTORS

Author:

Robert E. Sallis, M.D., FAAFP, Co-director of Sports Medicine Fellowship, Kaiser Permanente Medical Center, Fontana, California; Assistant Clinical Professor of Family Medicine; UCR/UCLA Biomedical Sciences Program; Team Physician, Pomona College, Rancho Cucamonga, California

AAFP Project Manager:

Sandy Shelton, CME Production Manager, Division of Continuing Medical Education

AAFP Staff Editor:

Cara Sloan, Senior CME Projects Editor, Division of Continuing Medical Education

AAFP CME Projects Coordinator:

Nina Carnoali, Senior CME Program Coordinator, Division of Continuing Medical Education

AAFP Editorial Assistant:

Julie McNamara, Manager, CME Marketing, Division of Continuing Medical Education

Illustrator:

Stephen Beebe, Kaiser Permanente, Los Angeles, California

Videographer:

Rick Tilley, Kaiser Permanente, Los Angeles, California

CME CREDIT INFORMATION

See insert for CME credit information and credit statement.

AAFP members wishing to obtain CME credit should complete and return the enclosed post-test to the CME Production Department, American Academy of Family Physicians, 11400 Tomahawk Creek Parkway, Leawood, Kansas 66211-2672. These credits will automatically be added to your continuing medical education records.

Physicians who are nonmembers should complete the post-test and return it to the CME Production Department, American Academy of Family Physicians, 11400 Tomahawk Creek Parkway, Leawood, Kansas 66211-2672. A letter documenting program completion will be sent automatically upon receipt of the post-test.

OBJECTIVES

Upon completion of this program, you should be able to:

1. State important history questions used to evaluate patients presenting with problems involving the shoulder, neck, elbow, wrist, hand, back, knee, foot and ankle.
2. Locate important anatomic landmarks in each of these areas and understand their clinical significance.
3. Perform essential exam maneuvers needed to effectively diagnose problems involving the shoulder, neck, elbow, wrist, hand, back, knee, foot and ankle.

INTRODUCTION

This video presentation is designed to give primary care physicians a practical review of essential examination techniques necessary to diagnose patients presenting with common musculoskeletal complaints. A systematic approach is presented, which includes a focused history followed by a thorough physical exam. The techniques reviewed in this presentation should enable the primary care physician to make confident evaluations and diagnoses.

This self-study program is divided into 7 modules:

1. Neck/shoulder
2. Elbow
3. Wrist/hand
4. Lower back
5. Hip
6. Knee
7. Ankle

To maximize learning, it is advised you watch the video presentation with a partner while carefully reviewing this syllabus material. At the end of each module, locate each of the anatomic landmarks on your partner (it may be helpful to mark them with an erasable pen). Next, review the list of “exam essentials” for each module and practice them on your partner.

You may consider viewing the companion “Joint Injection and Aspiration” self-study program as well. Together, these educational offerings can help the practicing family physician become more confident with diagnosing and managing patients with common musculoskeletal disorders.

Terminology

Before you begin this module, it may be helpful to review terms that will be used to describe various exam maneuvers and findings:

1. Valgus — describes the position of a joint when the distal segment is angled away from the midline of the body (eg, genu valgum is the knock-kneed position).
2. Varus — the opposite of valgus, in which the distal segment is angled toward the midline of the body (eg, genu varum is the bow-legged position).
3. Abduction — refers to motion away from the midline of the body.
4. Adduction — refers to motion toward the midline of the body.
5. Proximal — means closer to any point of reference; opposed to distal.
6. Distal — means further from any point of reference; opposed to proximal.
7. Volar — the palmar surface of the hand.
8. Dorsal — the posterior surface (or back) of the hand.

Shoulder and Neck Evaluation

Shoulder and Neck Exam Landmarks

Shoulder and Neck Exam Essentials

SHOULDER AND NECK EVALUATION

HISTORY

A thorough history is critical in evaluating patients with shoulder pain. Important questions include:

What was the mechanism of injury or overuse?

It is important to determine if this is a chronic injury related to overuse, or an acute injury related to trauma. Specifically ask what activities cause the pain. Most commonly, pain from an overuse injury will be related to repetitive overhead activity and will tend to worsen with activity and improve with rest. Keep in mind also that pain in the shoulder can radiate from a variety of sources, including the chest, abdomen and the cervical spine.

Are there symptoms of instability?

Ask the patient if they have ever had a dislocated shoulder. This injury will generally result in loosening of the static restraints of the shoulder (capsule and glenohumeral ligaments) and chronic problems of shoulder instability. Inquire if the shoulder “slips out of place” with throwing or other overhead motions. This is an obvious sign of glenohumeral instability. Instability is commonly seen in young, active patients with recurrent shoulder pain.

What is the location and character of pain?

Asking about the location of pain can be helpful in pinpointing its source, and can be confirmed by palpation. The character of the pain can be helpful in diagnosing rotator cuff problems. With rotator cuff tendinitis, the pain tends to worsen with activity, improve with rest and is typically located in the subacromial area. Pain from impingement syndrome is worse with overhead motions (such as washing hair or reaching for an overhead cupboard). Patients will often wake at night when rolling over onto an extended arm. Finally, pain from a rotator cuff tear will present as a dull, unrelenting ache (toothache-type pain). It often leads to severe night pain that prevents sleep and makes it hard to lie on the shoulder.

Are there mechanical symptoms (locking or popping)?

Popping or snapping in the shoulder with overhead motion is common but rarely of clinical significance. However, when it is painful or leads to a true blocking of motion, a labrum tear should be suspected.

What is the relationship of pain to the throwing motion?

Repetitive throwing commonly causes shoulder pain. The throwing motion can be simply divided into three phases: (1) cocking, (2) acceleration and (3) release/deceleration (*Figure 1*). Where in the throwing motion the pain occurs can be a clue to its cause. Pain during the cocking phase suggests anterior cuff tendinitis or anterior instability/subluxation. Pain during the acceleration phase suggests rotator cuff tendinitis or impingement. Pain during release/deceleration suggests posterior cuff tendinitis or posterior instability/subluxation (rare).

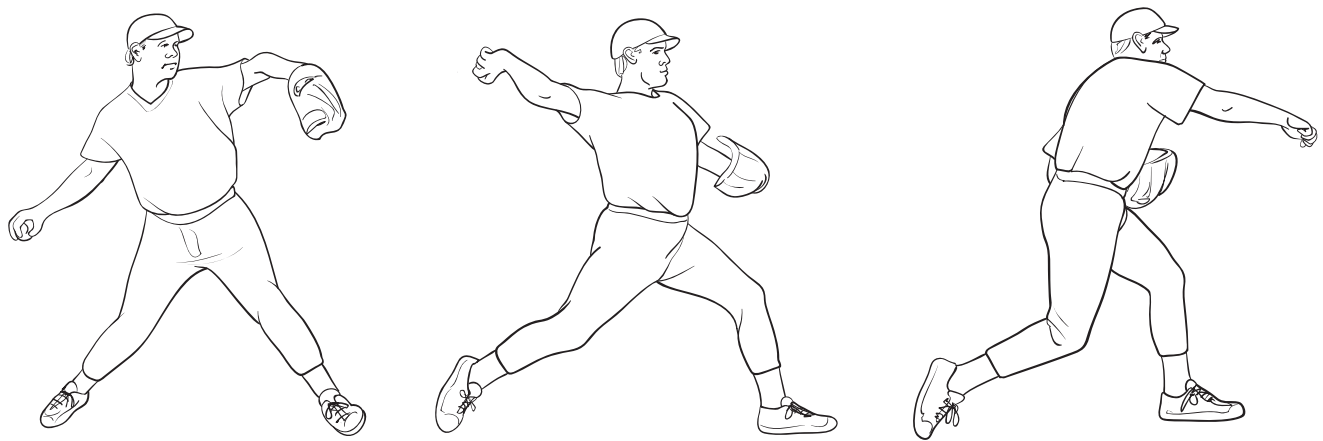

Figure 1. The throwing motion can be simply divided into three phases: (1) cocking, (2) acceleration and (3) release/deceleration.

EXAMINATION

When examining the shoulder, it is important to have the patient remove enough clothing so that both shoulders can be viewed and compared. Essential components of the shoulder exam include:

Inspection

Look at both exposed shoulders and compare for asymmetry. Muscle atrophy may suggest rotator cuff tear with disuse or nerve injury. Keep in mind that you may see asymmetry due to adaptive hypertrophy of the throwing shoulder in an athlete. Venous distension may suggest effort thrombosis (often only with exertion). Ecchymosis or swelling around the shoulder may suggest trauma or muscle tear.

Palpation

Palpate the shoulder for areas of tenderness (*Figures 2 and 2a*). Important areas to palpate include:

1. Sternoclavicular joint — tenderness suggests traumatic dislocation or osteoarthritis (OA).
2. Clavicle — tenderness suggests fracture or contusion.
3. Acromioclavicular (AC) joint — tenderness suggests AC separation, OA, or osteolysis. Three grades of AC separation are seen:
 - A. Grade I — tender, no bump.
 - B. Grade II — tender bump as distal clavicle elevates, but maintains contact with acromion.
 - C. Grade III — larger bump at distal clavicle that elevates above its articulation with the acromion.
4. Bicipital groove — tenderness suggests long head of biceps tendinitis or tear.
5. Glenohumeral joint line (anterior/posterior) — tenderness may suggest OA or labrum tear.
6. Subacromial space (anterior/lateral/posterior) — tenderness suggests rotator cuff tendinitis, impingement or tear.
7. Spine of the scapula — with supraspinatus muscle above the spine, and the infraspinatus and teres minor muscles below.

Figure 2. Locations of common causes of shoulder pain.

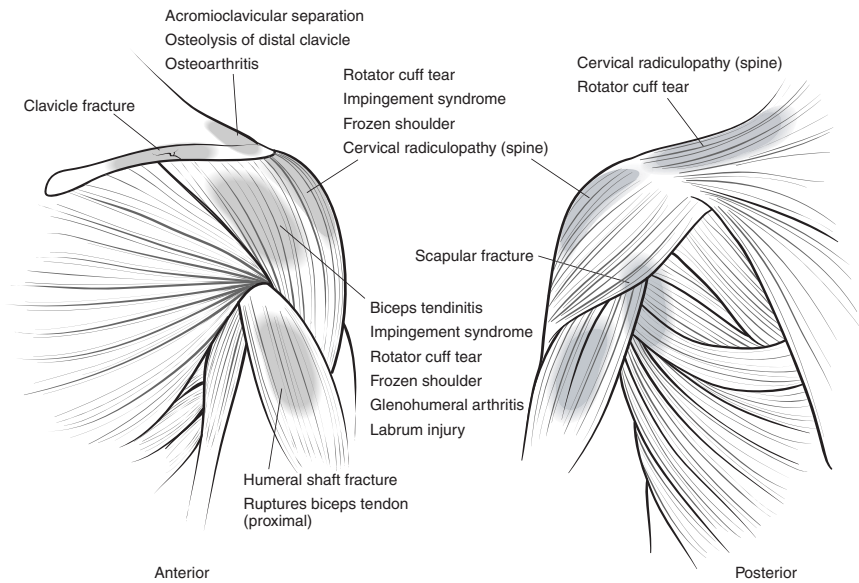
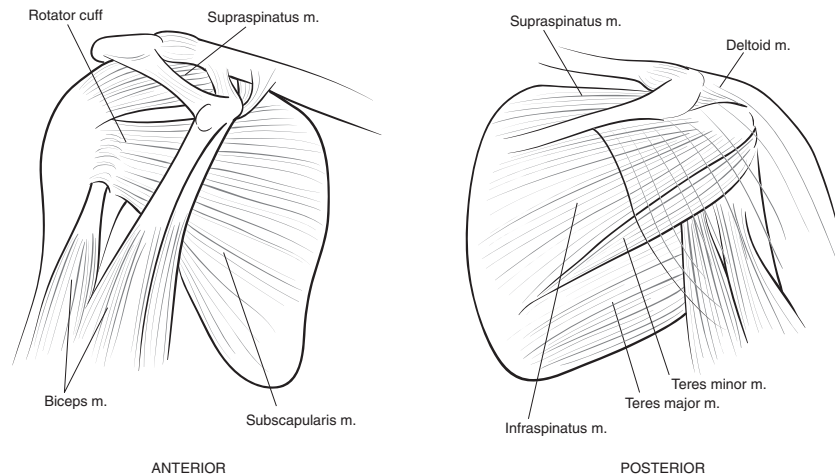


Figure 2a. Muscles of the rotator cuff.



Range of Motion (ROM)

Range of motion in the shoulder should be assessed both actively and passively. A loss of active motion alone suggests rotator cuff (RC) tear or nerve injury. A loss of both active and passive motion suggests a mechanical block (such as a labrum tear, adhesive capsulitis or severe impingement). The following motions should be assessed when checking ROM:

1. Forward flexion (180°)
2. Extension (45°)
3. Abduction (150°)
4. External rotation (90°)
5. Internal rotation (90°)
6. Horizontal adduction (130°)

The “Drop Arm Test” is the inability to lift or hold the arm in the 90° abducted position. When positive, a large rotator cuff tear or nerve injury is suggested.

Strength Testing

Strength testing of the rotator cuff is performed using resisted motion. Pain during resisted motions suggests tendinitis; weakness suggests a RC tear. It is essential to differentiate true weakness from a painful inhibition of strength that may be seen with severe tendinitis. The following resisted motions should be tested:

1. Internal rotation — subscapularis
2. External rotation — infraspinatus, teres minor (*Figure 3*)
3. Abduction — supraspinatus and deltoid
4. Abduction with thumbs down and 30° horizontal adduction (“empty can test”) — isolates supraspinatus (*Figure 4*)
5. Palms up with elbows bent to 15° flexion and resisted upward motion (Speed’s test) — biceps (*Figure 5*)
6. Simultaneous resisted supination and elbow flexion (Yergason’s test) — biceps



Figure 3. External rotation strength test (infraspinatus and teres minor).



Figure 4. “Empty can test” for supraspinatus.

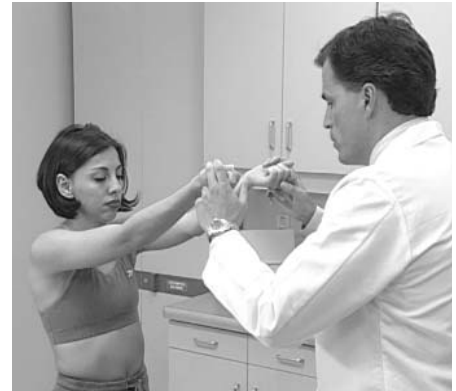

Figure 5. Speed’s test for biceps strength.

Impingement Signs/Impingement Test

Impingement signs are evaluated to diagnose the impingement syndrome. Pain or lack of motion with these maneuvers suggests impingement of the RC tendons in the subacromial space. Three impingement signs are commonly used:

1. Neer’s sign — extreme forward flexion with the forearm pronated (*Figure 6*)
2. Hawkin’s sign — 90° forward flexion of the shoulder with the elbow flexed to 90° then internal and external rotation movements of the shoulder (*Figure 7*)
3. Crossover sign — extreme horizontal adduction (this maneuver also worsens AC joint pain) (*Figure 8*)

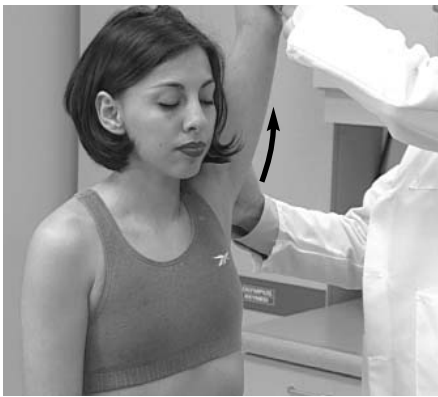

Figure 6. Neer's impingement sign.

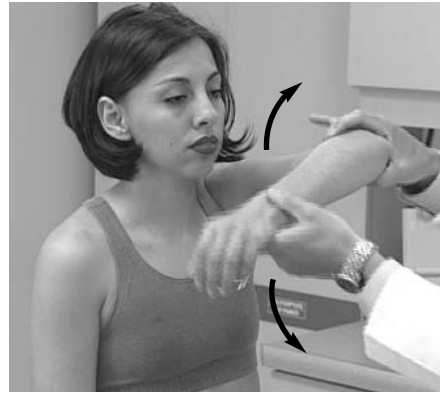


Figure 7. Hawk's impingement sign.

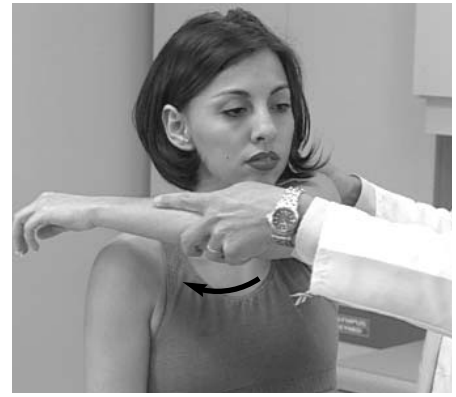

Figure 8. Crossover sign.

The impingement test involves injecting Lidocaine into the subacromial space. The above signs are repeated and relief of pain confirms impingement syndrome. RC strength testing should be re-tested after injection to relieve painful inhibition of strength and more accurately assess for RC weakness (tear).

Instability Tests

Several tests can be performed to assess for glenohumeral joint instability:

1. Apprehension tests — these tests are positive when they provoke an unpleasant sensation of the shoulder coming out of joint. Simple pain with these tests may be from rotator cuff or labrum injury rather than instability. Apprehension tests can be performed in both the anterior and posterior direction, although the vast majority of shoulder instability is anterior.
 - A. Anterior apprehension — performed with shoulder and elbow at 90°; apply an anterior force to the posterior shoulder pushing the humeral head anteriorly (*Figure 9*)
 - B. Posterior apprehension — performed with shoulder and elbow at 90°; apply a similar posterior force to the anterior shoulder pushing the humeral head posteriorly

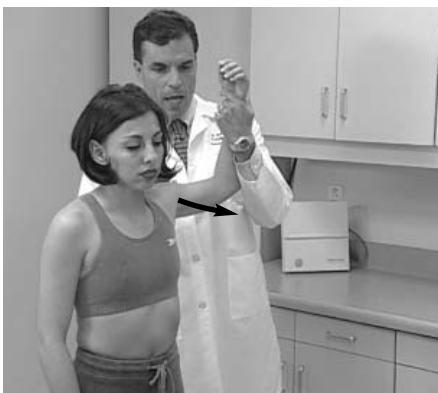

Figure 9. Anterior apprehension test.

2. Relocation test — this test is performed supine with shoulder and elbow bent to 90° and hanging off the edge of the exam table. The shoulder is then cranked into external rotation until discomfort is noted. Posterior pressure on the humeral head relieves discomfort in those with anterior instability. No change or worsening of pain suggests impingement (*Figure 10*).

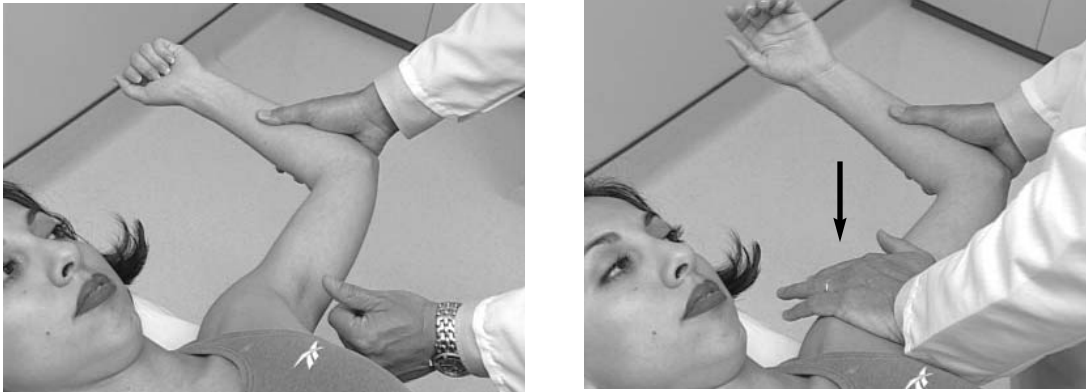

Figure 10. Relocation test — first place shoulder into maximal external rotation. Next, apply posterior pressure to humeral head.

3. Sulcus sign — performed with arms hanging at side. Downward pull on arm causes “sulcus” to form between acromion and humeral head with inferior instability (often suggests multi-directional instability). (*Figure 11*)

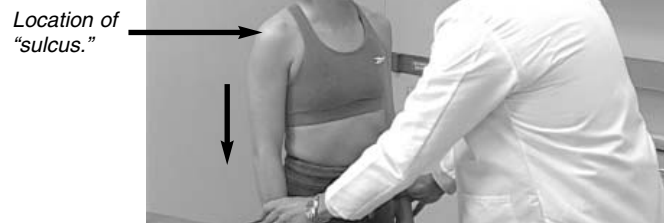


Figure 11. Sulcus sign.

Labrum Tests

Injury to the glenoid labrum can be difficult to detect clinically. The tests used to evaluate the labrum are analogous to tests used in the knee to detect meniscal injury:

1. Clunk test — performed with the patient supine or erect and the shoulder rotated through a full overhead ROM. A prominent clunk or pop may indicate a labrum tear.
2. Labrum grind test — performed sitting or supine with the elbow bent to 90° and shoulder abducted to 120°. The humeral head is compressed into glenoid while internally and externally rotating the humerus. Significant pain or clunking may suggest labrum injury (*Figure 12*).

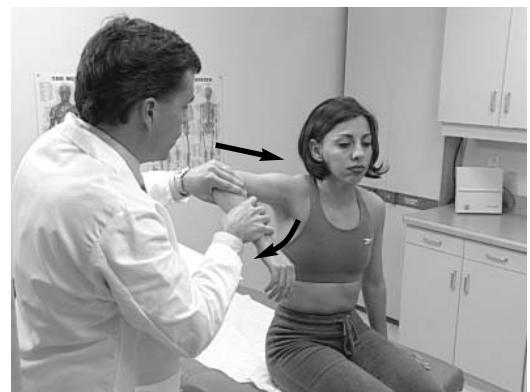

Figure 12. Labrum grind test.

3. O'Brien's test — the patient forward flexes both arms to 90° with 10° horizontal adduction and elbows extended. Apply a downward force to both arms, first with the thumbs up and again with the thumbs down. Increased pain in the thumbs-down position (compared to the thumbs-up) is suggestive of superior labrum, anterior/posterior (SLAP) injury to the labrum. Keep in mind that this maneuver will also aggravate AC joint pain (*Figure 13*).

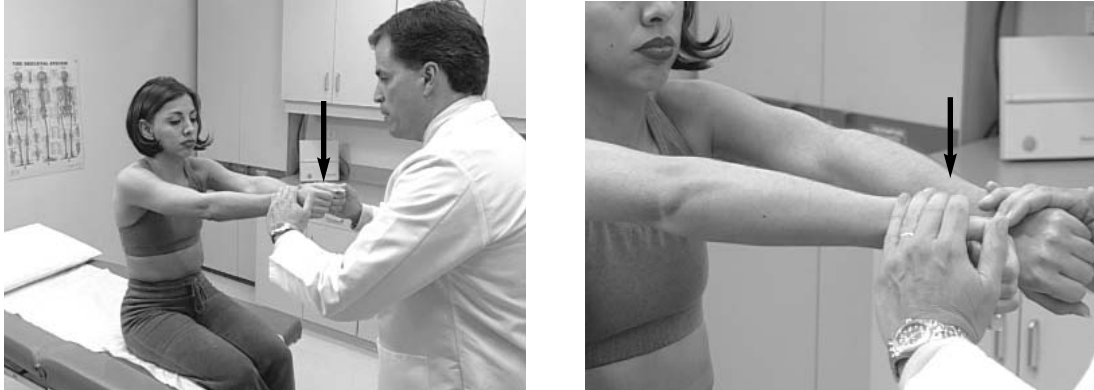

Figure 13. O'Brien's test. Check resisted upward motion, first with thumbs up and then with thumbs down.

Cervical Spine

The cervical spine is a common source of radicular pain to the shoulder. For this reason, the neck should be evaluated as a routine part of every shoulder exam:

1. Palpate over the spinous processes for bony tenderness or a step-off. Also palpate over the paraspinous muscles for tenderness or spasm.
2. Check neck range of motion (active, passive and resisted), including forward flexion (normally about 45°), extension (55°), twisting (70° each way) and side bending (40° each way). Ask if this reproduces shoulder pain.
3. Atlanto-axial compression test (Spurling's test) — performed by applying an axial load to the top of the head while the neck is twisted. Radicular pain to the shoulder and arm suggests cervical nerve root irritation (*Figure 14*).
4. Forward flexion test — forward flex the neck with the head turned toward the side. Radicular pain to ipsilateral arm suggests disc impingement on a cervical nerve root.

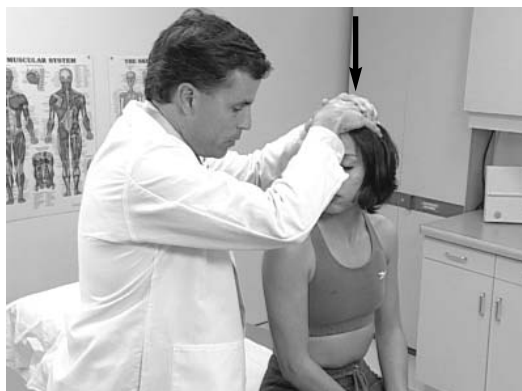

Figure 14. Spurling's test.

Shoulder And Neck Exam Landmarks

The following anatomic landmarks should be located:

Sternoclavicular (SC) Joint

Clavicle

Acromioclavicular (AC) Joint

Glenohumeral Joint Line (anterior and posterior)

Acromion Process

Coracoid Process

Biceps Tendon, Long Head and Bicipital Groove

Subacromial Space (anterior/lateral/posterior)

Spine of Scapula

Supraspinatus Muscle

Infraspinatus and Teres Minor Muscles

Medial Border Scapula

Trapezius Muscle

Spinous Processes of Cervical Vertebrae C5, C6, C7

Paraspinous Muscles

Shoulder and Neck Exam Essentials

- ___ 1. **Inspect** both exposed shoulders from front and back. Look for asymmetry from atrophy, swelling, ecchymosis, or venous distension.

- ___ 2. **Palpate** the shoulder for areas of tenderness.
 - A. Sternoclavicular joint
 - B. Clavicle
 - C. AC joint
 - D. Bicipital groove
 - E. Glenohumeral joint — anterior and posterior
 - F. Subacromial space and rotator cuff tendons

- ___ 3. **Range of motion** should be performed first actively and then passively (if necessary) comparing both shoulders.
 - A. Forward flexion (180°)
 - B. Extension (45°)
 - C. Abduction (150°)
 - D. External rotation (90°)
 - E. Internal rotation (90°)
 - F. Horizontal adduction (130°)

- ___ 4. **Strength** testing to look for muscle weakness and/or pain, performed as resisted movements.
 - A. Resisted internal rotation (subscapularis)
 - B. Resisted external rotation (infraspinatus, teres minor)
 - C. Resisted abduction (supraspinatus) — performed with thumbs down and arms forward 30°
 - D. Speed's test (biceps) — palms up with 15° bend in elbow
 - E. Yergason's test (biceps) — simultaneously resist wrist supination and elbow flexion

- ___ 5. **Impingement signs** cause pain and/or decreased motion when positive.
 - A. Extreme forward flexion (Neer's sign)
 - B. Extreme horizontal adduction (Crossover test) — also hurts with AC joint pathology
 - C. Internal and external rotation with 90° forward flexion at shoulder and 90° flexion at elbow (Hawkin's test)

Shoulder and Neck Exam Essentials (continued)

- ___ 6. **Instability** is assessed by checking for an apprehension sign.
 - A. Anterior apprehension (performed with shoulder at 90° abduction and elbow flexed at 90°; patient can be supine or erect)
 - B. Posterior apprehension (same position as anterior)
 - C. Sulcus sign (suggests inferior or multidirectional instability)
 - D. Relocation test (performed with shoulder at 90° abduction and external rotation, decreased pain with posterior pressure on humeral head indicates instability)

- ___ 7. **Labrum tests** are performed to look for tear.
 - A. Clunk test — performed with elbow at 90° flexion and shoulder brought through full overhead motion. Check for obvious clunk or pop
 - B. Labrum grind test — compress glenoid humerus (GH) joint while rotating arm, looking for pop or pain
 - C. O'Brien's test — resisted forward flexion at 90° with elbow extended, hurts more with thumb down than with thumb up if labrum pathology

- ___ 8. **Cervical spine** should be assessed as a possible etiology for shoulder pain.
 - A. Range of motion (flexion, extension, twisting, side bending)
 - B. Tenderness (spinous processes, paraspinous muscles)
 - C. Spurling's test — extend neck while twisting head to the side and apply axial load
 - D. Forward flexion test — forward flex neck with head turned toward side

Elbow Evaluation

Elbow Exam Landmarks

Elbow Exam Essentials

ELBOW EVALUATION

HISTORY

The evaluation of elbow problems begins with a thorough history. Important questions include:

What was the mechanism of injury or overuse?

Ask if there was an acute injury (trauma), or if this is a chronic problem (overuse)? Determine the specific activities that cause pain and by what mechanism (ie, throwing, tennis, lifting, etc.). Ask if the symptoms improve with rest and worsen with activity. This is typical of overuse injuries.

What is the character and location of the pain?

The character of the pain can be helpful diagnostically. A painful pop at the medial elbow while throwing may indicate an ulnar collateral ligament tear. Recurrent popping at the medial elbow associated with tingling to 4th and 5th fingers suggests ulnar nerve subluxation. Delayed pain (after activity or trauma) suggests an effusion or OA. Finally, pinpointing the exact location of the pain (front, back, medial, lateral) is extremely helpful and can be confirmed with palpation (*Figure 15*).

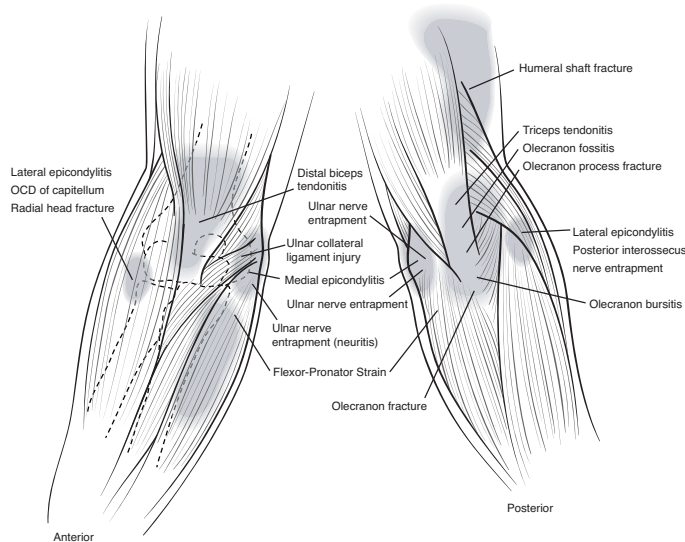


Figure 15. Common locations of elbow pain.

Are there mechanical symptoms?

Catching or locking in the elbow during motion may indicate a loose body in the joint. An elbow that is stiff or hard to bend may suggest effusion in the bursa or joint, or OA.

Is there swelling?

The most common area for swelling in the elbow is posterior at the olecranon bursa. This is most often seen after trauma (either acute or repetitive minor trauma). Swelling in the elbow joint is seen anterior, at the antecubital fossa.

What is the relationship of pain to the throwing motion?

Throwing creates a valgus stress at the elbow. This leads to compression forces at the lateral elbow (radial-capitellar joint) and tensile forces at the medial elbow (ulnar collateral ligament). These forces are greatest during the acceleration phase of the throwing motion. Pain can also occur at the posterior elbow at the end of the throwing motion as the elbow snaps into extension, causing the olecranon to jam into the olecranon fossa.

Are there past problems with the elbow?

Elbow pain at a young age (such as Little League elbow) is often a precursor to later problems. Classic Little League elbow causes medial pain at the epicondyle. Lateral elbow pain in a little leaguer is more ominous and can lead to osteochondritis dessicans (OCD) involving the radial-capitellar joint. Also keep in mind that imperfect healing after trauma can relatively weaken tissues and predispose to later injury.

EXAMINATION

When examining the elbow, it is important to compare to the uninvolved side. Essential elements of the elbow exam include:

Inspection

When inspecting the elbow, look for swelling, redness, warmth and carrying angle.

1. Compare the size of the elbows, looking for asymmetry. Keep in mind it is common to see adaptive hypertrophy in the dominant elbow of a thrower.
2. With elbow swelling, determine if in the bursa or joint. The most common site for swelling in the elbow is posterior, in the olecranon bursa. Swelling in the elbow joint will appear anteriorly and laterally.
3. Redness or warmth at the back of the elbow suggests olecranon bursitis or infection.
4. The carrying angle is formed by the upper and lower arm in the anatomic position. It is normally 5 to 10° in males and 10 to 15° in females. This angle can be altered by prior supracondylar fracture or infection.

Range of Motion (ROM)

ROM at the elbow should be evaluated by comparing to the uninvolved side. A lack of motion suggests stiffness (due to injury or arthritis) or a mechanical block within the joint (due to a loose body). Check the following motions:

1. Extension (0°) — slight flexion contracture in a thrower is common (*Figure 16*)
2. Flexion (150°) (*Figure 16*)
3. Pronation (70°) — palm down
4. Supination (90°) — palm up

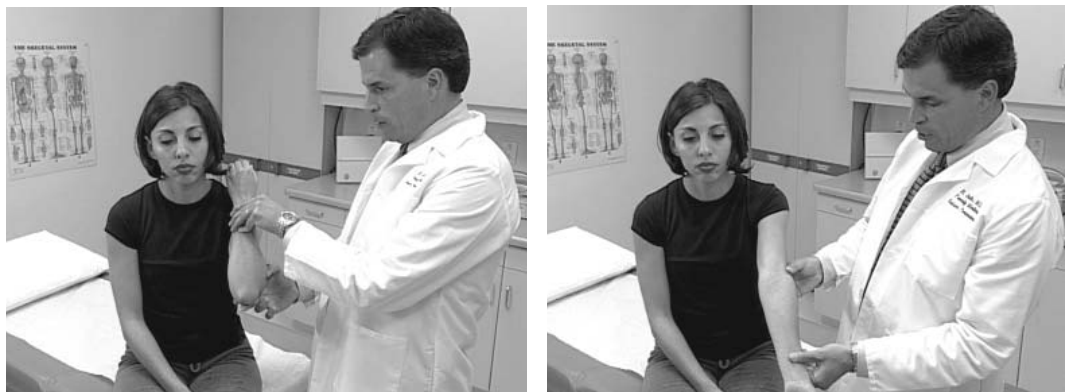

Figure 16. Testing elbow flexion and extension.

Strength Testing

Strength testing is performed as resisted movements. Pain with these resisted motions is commonly due to tendinitis or epicondylitis. Strength should be evaluated in the following motions:

1. Supination of wrist — resistance will aggravate lateral epicondylitis (supinators attach at lateral epicondyle). (*Figure 17*)
2. Pronation of wrist — resistance will aggravate medial epicondylitis (pronators attach at medial epicondyle). (*Figure 17*)
3. Extension of wrist — resistance will aggravate pain of lateral epicondylitis (wrist extensors attach at lateral epicondyle).
4. Flexion of wrist — resistance will aggravate pain of medial epicondylitis (wrist flexors attach at medial epicondyle).
5. Resisted long finger extension — pulls at the lateral epicondyle and will aggravate pain of epicondylitis. (*Figure 18*)
6. Elbow flexion — resistance tests biceps strength.
7. Elbow extension — resistance tests triceps strength.

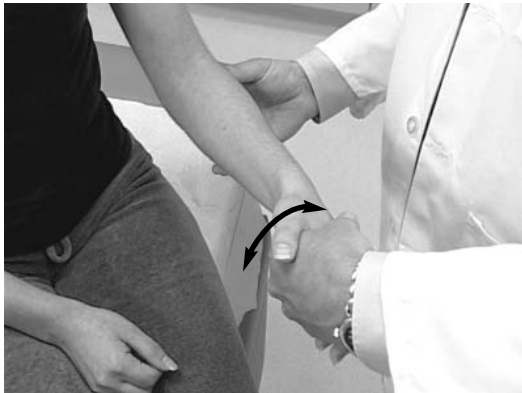

Figure 17. Testing supination and pronation strength.

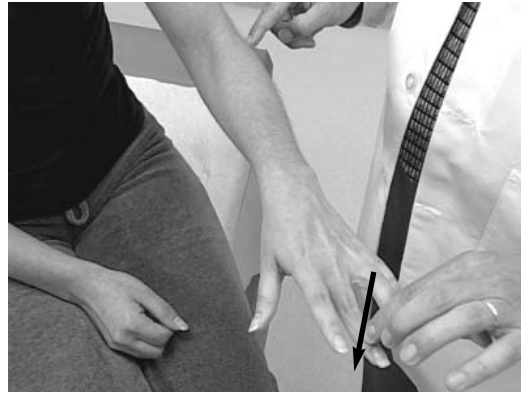

Figure 18. Resisted long finger extension will aggravate the pain of lateral epicondylitis.

Stretch Tests

These tests will aggravate pain caused by medial or lateral epicondylitis by pulling at the epicondyle.

1. Stretch the wrist into flexion or pronation, pulling at the lateral epicondyle and aggravating the pain of lateral epicondylitis.
2. Stretch the wrist into extension or supination, pulling at the medial epicondyle and aggravating the pain of medial epicondylitis.

Collateral Ligament Testing

The collateral ligaments of the elbow should be evaluated for pain and/or laxity. The medial collateral ligament is injured much more commonly than the lateral. Two tests are used to evaluate these ligaments:

1. Valgus/varus stress — performed with the shoulder in full external rotation and the elbow in 20° to 30° flexion (to unlock the olecranon from the olecranon fossa). Place your palm over the lateral elbow and using the opposite hand create a valgus stress (*Figure 19*) to assess the medial collateral ligament. A varus stress is used in an opposite fashion to assess the lateral collateral ligament. Check for pain and/or laxity to grade the severity of ligament injury.
 - A. Grade I (ligament stretched) — pain, with no laxity.
 - B. Grade II (partial tear) — pain with minimal laxity (soft end-point).
 - C. Grade III (complete tear) — pain with no good end-point.
2. Milking maneuver — bend affected elbow to 90° and full supination with thumb extended (*Figure 20*). Reach opposite arm under involved elbow and grasp thumb. Pulling laterally on thumb creates valgus stress at the medial collateral ligament of the affected elbow, and will result in pain if injured.

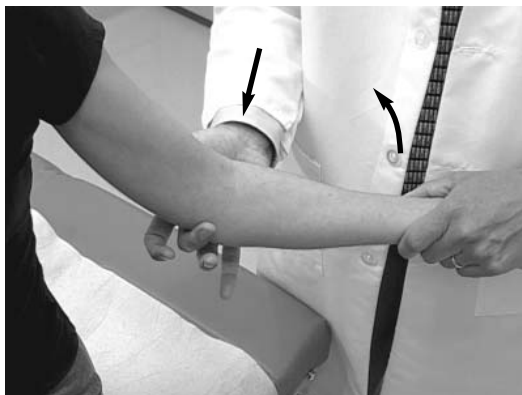

Figure 19. Medial collateral ligament testing with valgus stress.

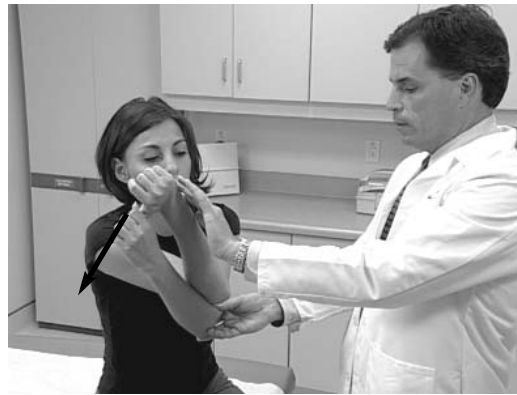

Figure 20. Milking maneuver for testing medial collateral ligament.

Palpation

Palpation is extremely helpful in pinpointing the source of elbow pain. It is helpful to generally localize elbow pain to anterior, posterior, medial or lateral. Important areas to palpate that cause pain in each of these areas include:

1. Anterior elbow
 - A. Distal biceps tendon
 - B. Anterior joint capsule
2. Posterior elbow
 - A. Distal triceps tendon
 - B. Olecranon process
 - C. Olecranon fossa
 - D. Olecranon bursae
3. Medial elbow
 - A. Medial epicondyle
 - B. Wrist flexor and pronator muscles
 - C. Medial collateral ligament
 - D. Ulnar nerve
4. Lateral elbow
 - A. Lateral epicondyle
 - B. Radial head
 - C. Radialcapitellar joint
 - D. Posterior interosseous nerve (entrapment can mimic lateral epicondylitis)

Elbow Exam Landmarks

The following anatomic landmarks should be located:

Distal Biceps Tendon

Olecranon Process and Fossa

Olecranon Bursa

Medial Epicondyle

Medial Collateral Ligament

Ulnar Groove and Nerve

Lateral Epicondyle

Radial Head

Radial – Capitellar Joint

Elbow Exam Essentials

- ___ 1. **Inspect** and compare both fully exposed elbows for swelling, redness, size, and carrying angle.

- ___ 2. **Range of motion** should be performed first actively and then passively (if necessary) while comparing both elbows.
 - A. Extension (0°)
 - B. Flexion (150°)
 - C. Pronation (70°)
 - D. Supination (90°)

- ___ 3. **Strength testing** is performed as resisted movements. Look for weakness and/or pain.
 - A. Flexion and extension of elbow
 - B. Flexion and extension of wrist
 - C. Pronation of wrist
 - D. Supination of wrist

- ___ 4. **Stability testing** is performed to assess the integrity of the elbow's collateral ligaments. Check for evidence of laxity and/or pain.
 - A. Valgus stress (elbow flexed at 20° to 30°) — stresses the medial collateral ligament
 - B. Varus stress (elbow flexed at 20° to 30°) — stresses the lateral collateral ligament
 - C. Milking maneuver — stresses the medial collateral ligament

- ___ 5. **Palpation** should identify areas of tenderness anterior, posterior, medial and lateral.
 - A. **Anterior**
 - a. Biceps tendon
 - b. Anterior joint capsule
 - B. **Posterior**
 - a. Triceps
 - b. Olecranon and olecranon fossa
 - c. Olecranon bursae
 - C. **Medial**
 - a. Medial epicondyle
 - b. Medial collateral ligament
 - c. Ulnar nerve
 - D. **Lateral**
 - a. Lateral epicondyle
 - b. Radiocapitellar joint

Wrist and Hand Evaluation

Wrist and Hand Exam Landmarks

Wrist and Hand Exam Essentials

WRIST AND HAND EVALUATION

HISTORY

Evaluation of the wrist and hand begins with a detailed history. Important questions include:

What was the mechanism of injury or overuse?

Common mechanisms of injury in the wrist include impact, weight bearing, twisting and throwing. Any of these mechanisms can cause an acute injury, or an overuse injury when repetitive. With an acute injury, ask about wrist position – was it flexed or extended? Did rotation occur? Throwing or racquet activities, as well as weight bearing events like gymnastics often cause chronic injury to the wrist.

What is the location and character of the pain?

Ask where the pain is felt (*Figure 21*). The exact location is extremely helpful (dorsal, volar, radial, ulnar) and can be confirmed with palpation (*Figure 22*). Ask what movements cause the pain and how frequently it occurs. Pain that improves with rest and worsens with activity is typical of an overuse injury. Asking how function is impaired can help gauge the severity of the pain.

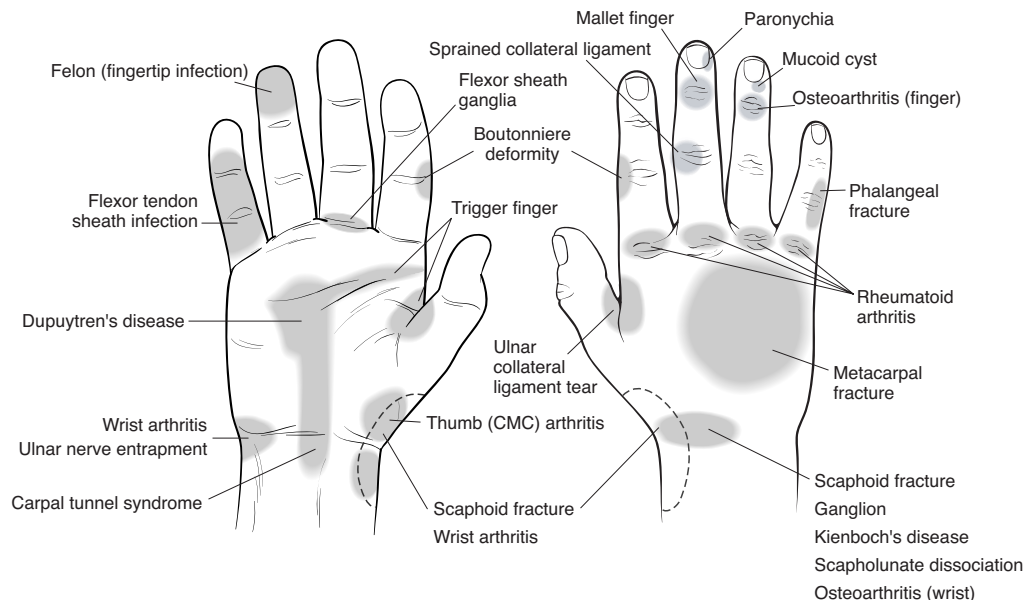


Figure 21. Locations of common causes of wrist and hand pain.

Are there abnormal sounds or sensations felt with movement?

A grinding sensation in the wrist often represents synovitis. Clunking may signal carpal instability, while snapping usually indicates subluxing tendons.

Is there swelling or stiffness?

This is commonly seen with various types of arthritis. OA is common in the distal interphalangeal (DIP) and proximal interphalangeal (PIP) joints, while rheumatoid arthritis (RA) is seen in the metacarpophalangeal (MCP) and PIP joints. Ganglion cysts commonly cause lumps in the wrist and hand.

Is there burning, tingling, numbness or weakness?

Various nerve entrapments can cause these symptoms to radiate to the wrist and hand. The location of symptoms can suggest which nerve is entrapped. Keep in mind the neck may be a source of nerve entrapment and radicular symptoms as well. Ask if neck movements aggravate pain in the wrist and hand.

Previous injury or medical problems?

Ask about previous wrist injury or surgery. Also ask about any orthopedic or rheumatologic disorders, as well as a history of diabetes or thyroid disorder.

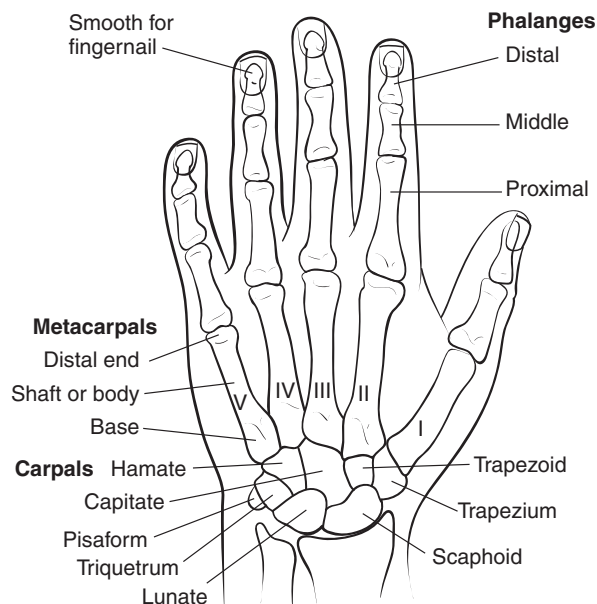


Figure 22. Bony anatomy of the wrist and hand.

EXAMINATION

Key aspects of the wrist and hand exam include:

Inspection

Should compare side to side, looking for:

1. Swelling or masses in the joints or soft tissue, commonly from arthritis or a ganglion.
2. Redness or warmth, which may suggest inflammation or infection.
3. Atrophy of muscles (can be seen with severe nerve injury or entrapment).

Range of Motion

This should be assessed first actively and then passively, generally following the rule of 90s. Compare side to side looking for deficits in range of motion.

1. With elbows at sides, palms should turn directly upward (90° supination) and downward (90° pronation) without pain.
2. With hands pressed together, wrists should extend (dorsiflex) and flex (palmarflex) approximately 90° (Figure 23).

3. Ask the patient to make a fist with all fingertips touching the palmar crease. In this position, each MCP and IP joint is flexed to 90°.
4. Ask the patient to touch the tip of thumb to base of the pinkie.

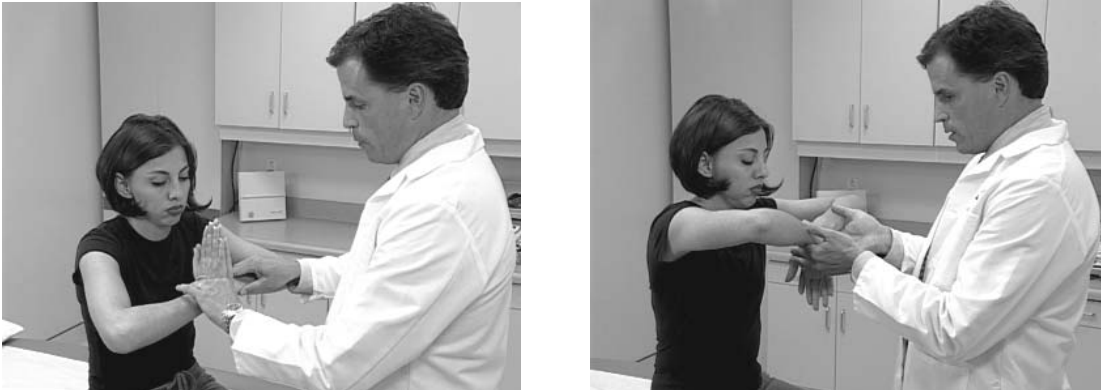

Figure 23. Testing wrist extension and flexion.

Strength Testing

Strength should be tested as follows, looking for pain or weakness:

1. Fully flex and then extend wrist against resistance. This should be painless (*Figure 24*).
2. Ask the patient to grip your finger. This should be painless and you should not be able to pull your finger free (*Figure 25*).
3. Ask the patient to pinch a piece of paper between thumb and index finger, and again between thumb and long finger. It should take a significant tug to get the paper free.

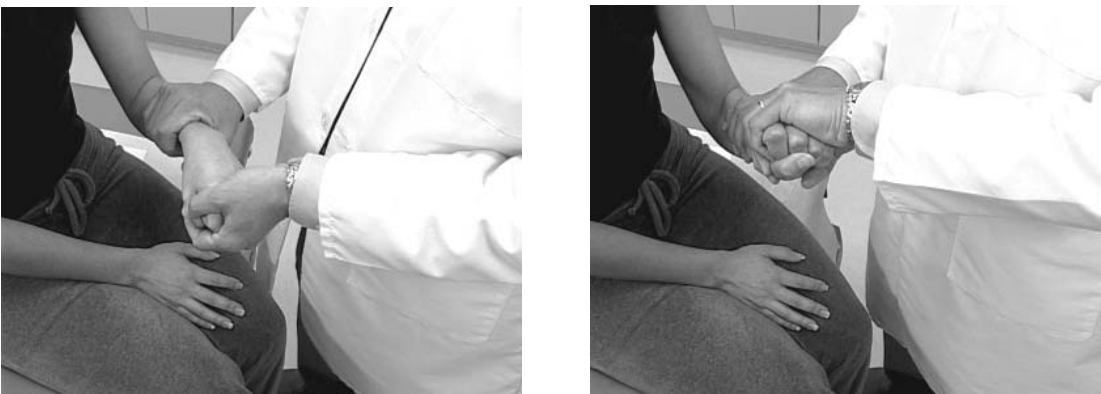

Figure 24 . Testing wrist flexion and extension strength.

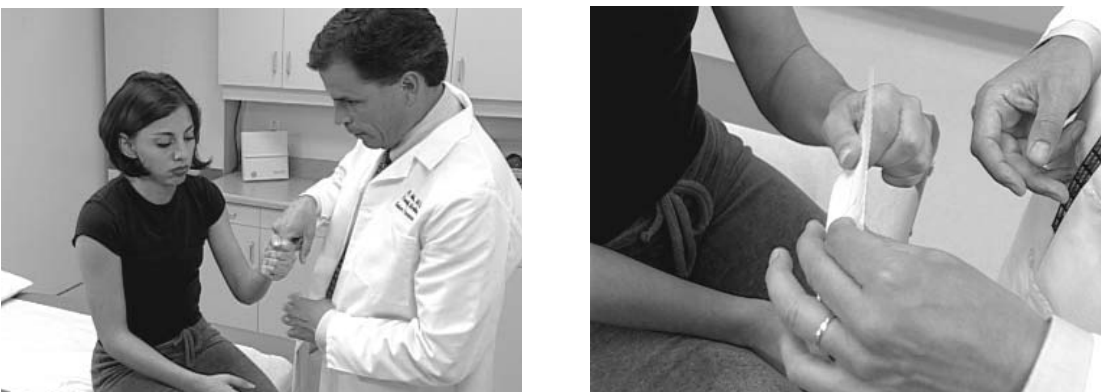


Figure 25. Testing hand grip and pinch strength.

Motor Examination

Assess motor function of the hand using the following tests:

1. Flex and extend thumb — checks median and radial nerves.
2. “Scissor” fingers together and apart — checks ulnar nerve.
3. With hand on flat surface palm up, raise thumb against resistance — checks median nerve.

Circulation

Evaluate circulation to the hand by palpating for radial and ulnar pulse (*Figure 26*).

Occasionally, the ulnar pulse may not be easily palpable. Also, check capillary refill. After pressure is applied to the finger pad, color should return within 2 seconds.



Figure 26. Palpating the radial pulse.

Sensation

Evaluate sensations by checking for light touch, pinprick, and 2-point discrimination (separated 7 mm or more) on finger pads. Specifically check the tip of thumb (median nerve), tip of 5th finger (ulnar nerve) and dorsum of hand (radial nerve).

Palpation

Palpate the following areas of the **wrist** for tenderness or deformity:

1. Radial dorsal side
 - A. Radial styloid
 - B. Scaphoid (anatomic snuff box)
 - C. 1st CMC joint (arthritis)
 - D. Abductor pollicis longus (APL) and extensor pollicis brevis (EPB) tendons (deQuervain’s)
2. Central dorsal side
 - A. Lunate (Kienbock’s disease or scapholunate dissociation) and capitate
 - B. Extensor carpi radialis longus and brevis (intersection syndrome can occur where they cross APL and EPB tendons)
 - C. Ganglion cysts common (may be occult)
3. Ulnar dorsal side
 - A. Ulnar styloid
 - B. Triquetrum and hamate bones
 - C. Triangular fibrocartilage complex (TFCC)

4. Radial volar side
 - A. Scaphoid tubercle
 - B. Long finger flexors and palmaris longus
 - C. Median nerve (carpal tunnel) — at middle volar wrist
5. Ulnar volar side
 - A. Hook of hamate and pisiform bones
 - B. Ulnar nerve and artery (Guyon's canal)

Palpate the following areas of the **hand** for tenderness or deformity:

1. Dorsal side
 - A. Extensor tendons
 - B. Metacarpals and phalanges
2. Volar side
 - A. Flexor tendons (both flexor digitorum profundus and superficialis)
 - B. Palmar aponeurosis (thickened with Dupuytren's contracture)
3. Joints
 - A. MCP, PIP and DIP
 - B. Collateral ligaments

Ligament and Tendon Testing

It is important to stress the ligaments in injured areas to evaluate for possible tear. Commonly injured ligaments include:

1. Collateral ligaments of the fingers — assess these ligaments applying a varus and valgus stress to the injured joint. Laxity is indicative of ligament tear (*Figure 27*).
2. Ulnar collateral ligament of the thumb — this is tested by applying an abduction stress to the 1st MCP joint with the thumb both flexed and extended. Pain during this test suggests a strain of the ligament, while laxity suggests a tear (*Figure 28*).
3. DIP extensor and flexor tendons — evaluate the extensor and flexor tendons of the fingers by stabilizing the PIP joint and asking the patient to both flex and extend the DIP joint. The inability to extend suggests rupture of the extensor tendon (Mallet finger), while the inability to flex suggests rupture of the flexor tendon (Jersey finger).



Figure 27. Testing the PIP collateral ligament.

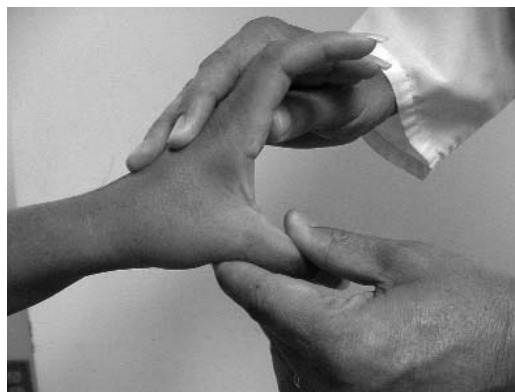

Figure 28. Testing the ulnar collateral ligament of the thumb for pain and/or laxity.

Special Tests

There are several important diagnostic-specific tests that are commonly performed in evaluation of the wrist and hand. These include:

1. Carpal tunnel syndrome tests — these tests will typically aggravate symptoms associated with carpal tunnel syndrome into the 1st – 3rd fingers.
 - A. Tinel's Test — performed by tapping on the volar side of the wrist over the median nerve (*Figure 29*).
 - B. Phalen's Test — performed by having the patient hold the wrist in a maximally flexed position (*Figure 30*).
 - C. Carpal tunnel compression test — performed by pressing firmly over the carpal tunnel for up to 30 seconds (*Figure 31*).

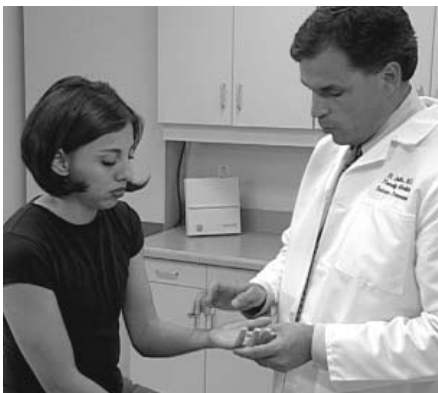

Figure 29. Tinel's test.

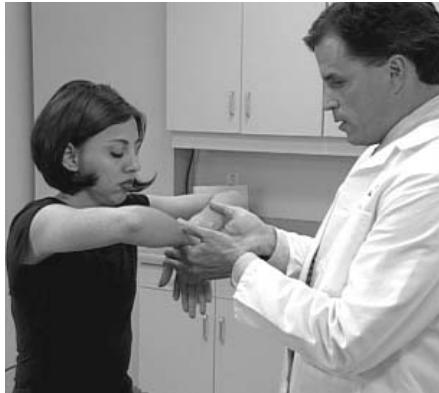

Figure 30. Phalen's test.



Figure 31. The carpal tunnel compression test.

2. Finkelstein's test — performed by having the patient first flex their thumb across the palm and then flex the other 4 fingers around it (*Figure 32*). Next ask the patient to ulnar deviate the wrist. Significant pain with this maneuver is suggestive of deQuervain's tendinitis.



Figure 32. Finkelstein's test.

3. Arthritis of the thumb (1st CMC joint) tests — these tests will aggravate the pain associated with this condition.

- A. Watson stress test — with the hand resting palm up and all fingers extended, the thumb is pushed down (*Figure 33*).
- B. Grind test — grasp the affected thumb and apply axial pressure moving the joint in a circular motion at the same time.



Figure 33. Watson stress test.

Wrist And Hand Exam Landmarks

The following anatomic landmarks should be located:

Proximal Wrist Crease

Carpal Tunnel (median nerve)

Thumb Crease

Palmaris Longus Tendon

Radial Styloid

Snuff Box

Radial Artery

Hook of Hamate

Triangular Fibrocartilage Complex

Ulnar Styloid

Wrist And Hand Exam Essentials

- ___ 1. **Inspect** both wrists and hands for any redness, warmth, swelling or atrophy.
- ___ 2. **Palpate** for areas of tenderness. Should specifically palpate these areas:
 - A. Anatomic “snuff box” for suspected scaphoid fracture
 - B. Radial styloid (tender with deQuervain’s tendinitis) and CMC joint of thumb
 - C. Carpal tunnel (median nerve)
 - D. Canal of Guyon (between pisiform and hook of hamate — ulnar nerve runs here)
 - E. Triangular fibrocartilage complex (TFCC) at distal ulna
 - F. Dorsum of wrist and hand (extensor tendons)
 - G. Palmar aponeurosis
 - H. All MCP, PIP and DIP joints of fingers
- ___ 3. **Range of motion** testing at wrist and hand.
 - A. Wrist flexion (80°) – ie, palm turned toward forearm
 - B. Wrist extension (70°)
 - C. Wrist ulnar deviation (30°)
 - D. Wrist radial deviation (20°)
 - E. Finger flexion and extension (palpate for volar popping)
- ___ 4. **Strength testing** with manually resisted motions listed above, as well as:
 - A. Grip strength
 - B. Opponens strength – resist thumb opposition
- ___ 5. **Sensory testing**
 - A. Radial nerve — dorsum of hand from 3rd digit to thumb (most at 1st and 2nd web space)
 - B. Median nerve — palmar aspect of hand from 3rd digit to thumb (most at tip of index finger)
 - C. Ulnar nerve — palmar and dorsal aspects of 4th and 5th digits (most at tip of little finger)
- ___ 6. **Special tests**
 - A. CMC stress test and grind test
 - B. Finkelstein’s test for deQuervain’s tendinitis
 - C. Tinel’s and Phalen’s tests for carpal tunnel syndrome
- ___ 7. **Ligament and tendon testing**
 - A. Ulnar collateral ligament of the thumb (skier’s thumb)
 - B. Collateral ligaments of the interphalangeal joints
 - C. DIP extensor tendons (mallet finger) and flexor tendons (jersey finger)
- ___ 8. **Miscellaneous**
 - A. Ganglion cysts
 - B. Paronychia
 - C. Felon

Lower Back Evaluation

Lower Back Exam Landmarks

Lower Back Exam Essentials

LOWER BACK EVALUATION

HISTORY

A complete history is essential in the evaluation of patients with lower back problems. Important questions include:

What was the mechanism of injury or overuse?

Ask if there has been acute trauma or injury. Also ask if there has been a recent history of excessive lifting or bending.

How severe is the pain?

Gauge the severity of patients' pain by asking if they are able to work and what activities the pain prevents them from doing. Also ask what they have used to relieve the pain, and if it worked.

Where is the pain located?

Location of the patient's back pain can be suggestive of its etiology (*Figure 34*).

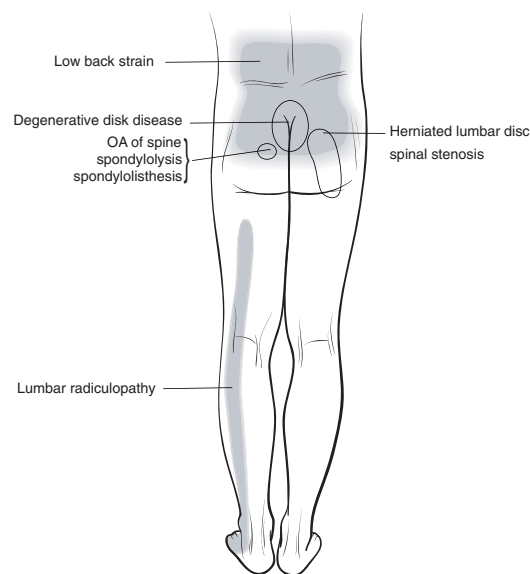


Figure 34. Locations of common causes of back pain.

Evaluate for “Red Flags”

Ask about symptoms which could indicate a more serious etiology for back pain:

1. **Cancer** (primary or metastatic) — ask about a history of cancer, as well as recent weight loss, rest pain or pain lasting more than 4 to 6 weeks despite therapy. Cancer is more common in patients older than 50 years.
2. **Spinal Infection** — ask about recent infection (urinary tract or skin), fever or rest pain. Infection is more common in those with immune-compromised states (diabetes, steroid use, human immunodeficiency virus, organ transplant) or intravenous drug use.
3. **Fracture** (usually compression fracture) — ask about recent trauma or use of corticosteroids. Fracture risk is increased in patients older than 70 years or with a history of osteoporosis.

4. **Sciatica** — ask about pain radiating down the posterior or lateral aspect of the leg to below the knee, as well as numbness, paresthesia or motor loss in legs. Sciatica pain tends to worsen with cough, sneeze or Valsalva.
5. **Cauda Equina Syndrome** — ask about bilateral lower extremity weakness, numbness, progressive neurological deficit or saddle anesthesia. Also ask about recent urinary incontinence/retention or fecal incontinence.
6. **Ankylosing Spondylitis (AS)** — ask about morning stiffness. Pain from AS usually begins slowly, persists at least 3 months and improves with exercise. The age of onset is usually younger than 40 years.

EXAMINATION

When examining a patient with back pain, make sure to remove clothing to expose the entire back and sacral area. Key components of the back exam include:

Inspection

Inspect the entire back for redness, asymmetry, deformity, scoliosis or abnormal hair growth.

Palpation

Palpate for areas of tenderness (*Figure 35*). Important areas to check include:

1. Spinous processes (look for a step-off at L4-S1 suggestive of spondylolisthesis)
2. Paraspinous muscles
3. Sacroiliac joints
4. Tip of coccyx
5. Firm percussion over the posterior spine may aggravate pain associated with infection, tumor or nerve impingement.
6. Place hands on both iliac crests and compare height to assess for leg length inequality.

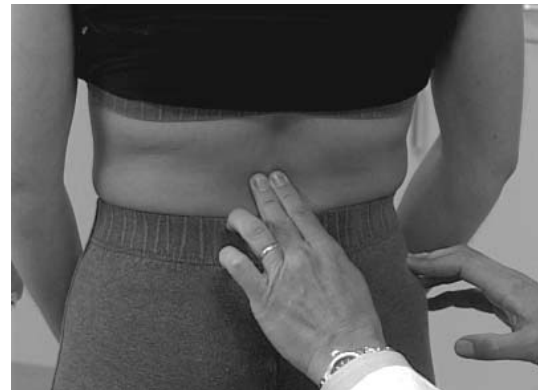

Figure 35. Palpating the lumbar spinous processes.

Range of Motion

The range of motion of the back should be evaluated. Look for deficits or excessive pain. Key motions include:

1. Forward flexion (normally 80 to 90°) can measure distance of fingertips from floor – this loads the discs and is thus more likely to increase disc pain. Be sure to observe from behind when bent forward to look for asymmetry of the back suggestive of scoliosis.
2. Extension (20 to 30°) – loads the facets and thus is more likely to increase facet pain (*Figure 36*).
3. Lateral bending (20 to 30° in each direction) – stretches muscle and is more likely to aggravate pain from muscle strain.
4. Twisting (30 to 40° in each direction) – also stretches muscle and increases pain from this source.

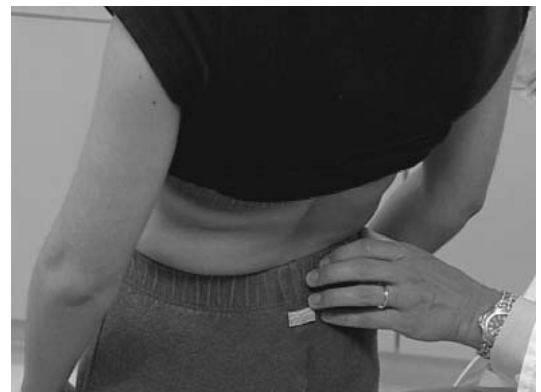

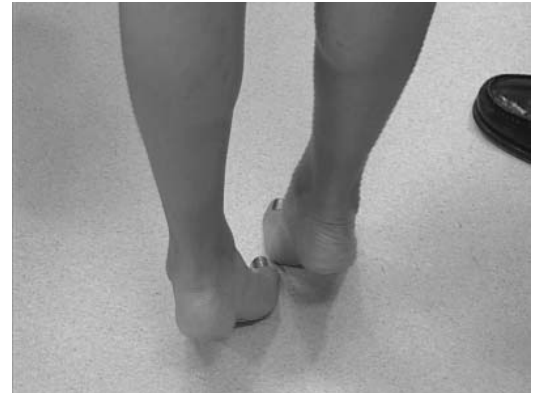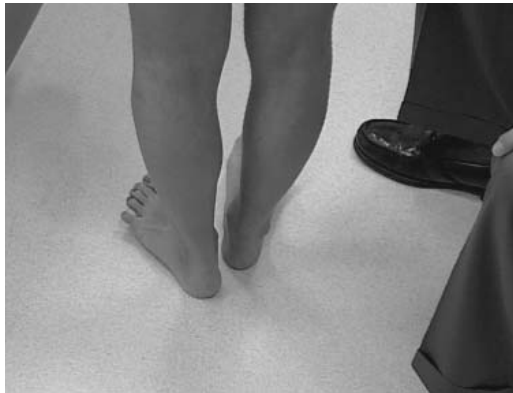Figure 36. Assessing back extension.

Strength Testing

The strength of muscles innervated by key nerve roots exiting the lumbar-sacral spine should be evaluated. Weakness suggests irritation of these nerve roots from disc or bony pathology. These include:

1. Heel walking (anterior tibial muscles; L4). (*Figure 37*)
2. Toe walking (gastroc-soleus muscles; S1). (*Figure 37*)
3. Resisted great toe dorsiflexion (L5). (*Figure 38*)

*Figure 37.
Checking
heel and
toe walking.*



*Figure 38.
Checking
dorsiflexion
strength of
great toe.*



Neurologic Exam

A focused neurologic exam should be performed in patients with lower back pain to include:

1. Deep tendon reflexes (knee jerk – L4 nerve root; ankle jerk – S1 nerve root).
2. Straight-leg raise – this test is performed by lifting the leg, with the knee extended, in the sitting (or supine) position (*Figure 39*). Pain radiating past the knee suggests sciatica, often caused by disc herniation in the lumbar-sacral area (L5 and S1 nerve roots). Dorsiflexion of the ankle during the straight-leg raise test increases sciatic tension and pain, while plantar flexion relieves sciatic tension and pain.
3. Ankle clonus may be elicited by sudden passive ankle dorsiflexion and result in repetitive uncontrolled ankle twitches. This suggests an upper motor neuron lesion, such as proximal spinal cord compression.

4. Crossed straight-leg raise test is performed by doing a straight-leg raise test on the opposite (uninvolved leg). If this maneuver aggravates the sciatica pain in the opposite leg, it is highly suggestive of sciatica.
5. Consider rectal exam (to check for decreased sphincter tone and perianal sensation) when cauda equina syndrome is suspected.

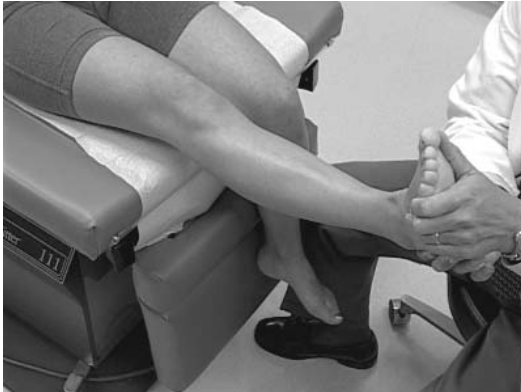

Figure 39. Straight-leg raise. Pain from sciatica should worsen with dorsiflexion of the ankle.

Special Tests

Special tests of the back include:

1. Stork test (one-leg standing hyperextension test) – performed by having the patient hyper-extend the back while standing on one leg. This position will aggravate pain associated with spondylolysis, spondylolisthesis or sacroiliac (SI) joint dysfunction.
2. Patrick's or FABER test – performed by placing the hip and leg into the figure-4 position (flexion, abduction and external rotation). This position will aggravate SI joint pain (*Figure 40*).

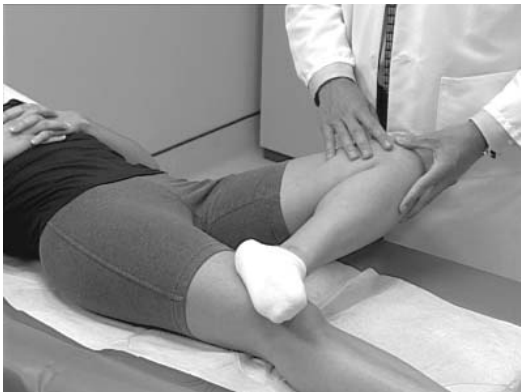

Figure 40. FABER (Flexion, Abduction and External Rotation) test.

Lower Back Exam Landmarks

The following anatomic landmarks should be located:

Iliac Crests (Level of L4)

Paraspinous Muscles

Spinous Process L4, L5, S1

Tip of Coccyx

Sacroiliac Joints

Ischeal Tuberosity

Lower Back Exam Essentials

- ___ 1. **Inspect** entire back for redness, asymmetry, deformity, scoliosis or hair growth.

- ___ 2. **Palpate** for areas of tenderness.
 - A. Spinous processus (look for a step-off at L4-S1)
 - B. Paraspinous muscles
 - C. Sacroiliac joints
 - D. Tip of coccyx
 - E. Percussion over spine (may elicit pain with infection, tumor or nerve impingement)

- ___ 3. **Range of motion testing** should be observed from behind.
 - A. Forward flexion — worsens disc pain (observe for asymmetry seen with scoliosis)
 - B. Extension — worsens facet pain
 - C. Lateral bending — worsens muscle pain
 - D. Twisting — worsens muscle pain

- ___ 4. **Strength testing**
 - A. Heel walking (anterior tibial muscles; L4)
 - B. Toe walking (gastroc-soleus muscles; S1)
 - C. Resisted great toe dorsiflexion (L5)

- ___ 5. **Neurologic exam**
 - A. Deep tendon reflexes (knee jerk – L4, ankle jerk – S1)
 - B. Straight-leg raise (pain radiating past knee indicates sciatic pain)
 - C. Dorsiflexion of ankle during straight-leg raise test increases sciatic tension and pain
 - D. Plantar flexion at ankle during straight-leg raise relieves sciatic tension and pain
 - E. Ankle clonus — may occur with sudden ankle dorsiflexion (indicates long tract spinal cord involvement)
 - F. Consider rectal exam (for tone) and check for perianal sensation (cauda equina syndrome)

- ___ 6. **Special tests**
 - A. Patrick’s or FABER test — flexion, abduction and external rotation at the hip will elicit SI joint pain
 - B. Stork test (one–leg standing hyperextension test) — elicits lower back pain associated with spondylolysis, spondylolisthesis or SI dysfunction

Hip Evaluation

Hip Exam Landmarks

Hip Exam Essentials

HIP EVALUATION

HISTORY

Evaluation of a patient with hip pain should begin with a thorough history. Important questions include:

What was the mechanism of injury?

Ask if there was acute trauma or if this chronic pain is due to overuse.

What is the duration and location of the pain?

Ask how long the pain has been present. Also ask the general location of the pain – is it in the front, back or side (*Figure 41*). Suspect the following based on location of the pain:

1. Front — suspect hip joint (OA, fracture, osteochondritis dissecans [OCD]).
2. Side — suspect trochanteric bursa, iliotibial (IT) band, meralgia paresthetica.
3. Back — suspect hip joint, sciatica, SI joint, hamstring pull, ischeal bursitis.

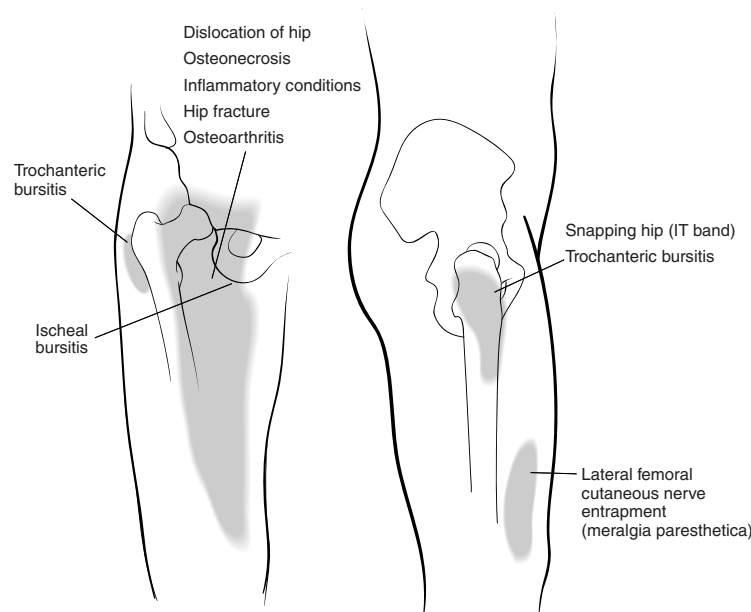


Figure 41. Locations of common causes of hip pain.

Is there pain in the back or down the leg?

Pain from sciatica may start at the posterior hip (sciatic notch) and then radiate down the back or side of the leg. Also keep in mind that hip pathology may refer pain to the inner thigh or knee (via obturator nerve irritation).

Is there snapping or clicking with movement?

When this occurs at the lateral hip it is usually due to the IT band or gluteus maximus snapping over the greater trochanter. If it occurs on the medial side it is usually due to the iliopsoas tendon popping over the lesser trochanter or hip subluxation.

Does the problem affect gait or activity?

The presence of a limp, limitation of activity or the inability to sit and remove footwear can indicate the significance of a hip problem.

Is there a history of prior hip problems?

Childhood problems (avascular necrosis of the femoral head [Legg-Perthe's disease], slipped capital femoral epiphysis [SCFE], hip dislocation) frequently lead to significant problems later in life.

What is the age of the patient?

The most common conditions affecting the hip vary, depending on the patient's age:

1. Newborn — congenital hip dislocation, synovitis
2. 2 to 8 yrs. — Legg-Perthe's, synovitis
3. 10 to 14 yrs. — slipped capital femoral epiphysis (SCFE)
4. 14 to 25 yrs. — stress fracture, synovitis
5. 20 to 60 yrs. — avascular necrosis, synovitis, RA
6. 45 to 60 yrs. — OA, synovitis
7. 65+ yrs. — OA, fracture, stress fracture

EXAMINATION

Clothing should be removed to expose and compare both hips. Essential aspects of the hip exam include:

Inspection

Inspect both hips from the front, back and sides. Note asymmetry due to muscle wasting or swelling. Observe gait up and down the hall checking for limp.

Palpation

Palpate the hip in the following areas for tenderness:

1. Anterior hip joint — pain from OA, fracture or avascular necrosis (AVN)
2. Anterior superior iliac spine — sartorius attachment
3. Anterior inferior iliac spine — rectus femoris attachment
4. Greater trochanter — bursa overlies
5. Iliotibial band — can rub over greater trochanter with hip flexion
6. Posterior superior iliac spine (PSIS) — posterior tip of iliac bone
7. SI joint — lies just under the PSIS, common source of pain
8. Sciatic notch — located slightly below the SI joint — tender with sciatica
9. Gluteus muscle — main extensor of the hip
10. Ischial tuberosity — hamstrings attach here
11. Proximal hamstring muscles

Range of Motion (ROM)

Hip ROM should be tested looking for pain or limitation. Check the following motions:

1. Internal rotation (30°) — stabilize knee at 90° flexion with patient seated and move foot away from midline (*Figure 42*).

2. External rotation (60°) — in the same position, move foot toward midline (lost early with hip OA) (*Figure 42*).
3. Flexion (120°) — with patient supine, grasp bent knee and pull to chest (stop when back flattens) (*Figure 43*).
4. Extension (15°) — while prone, lift leg off table (*Figure 43*).
5. Abduction (45°) — with patient supine, hold ankle and pull leg away from midline (*Figure 44*).
6. Adduction (30°) — with patient supine, pull leg toward midline (until pelvis tilts) (*Figure 44*).

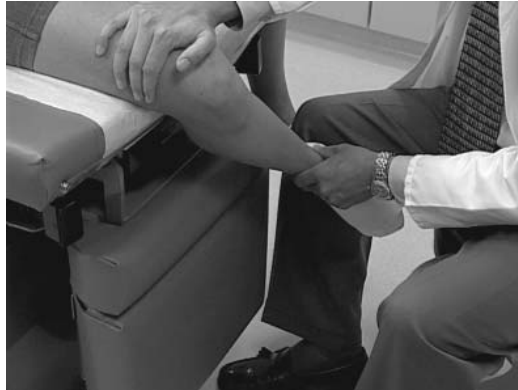
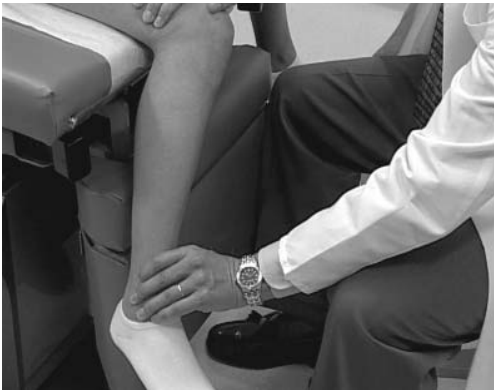
Figure 42. Hip internal and external rotation.

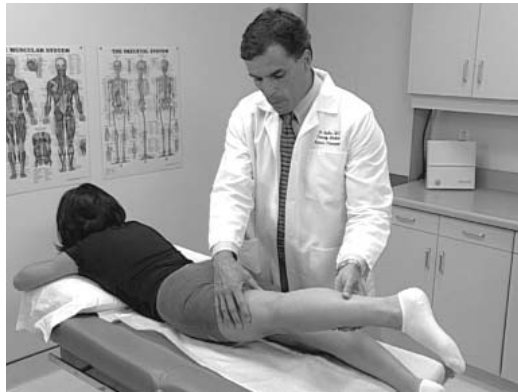
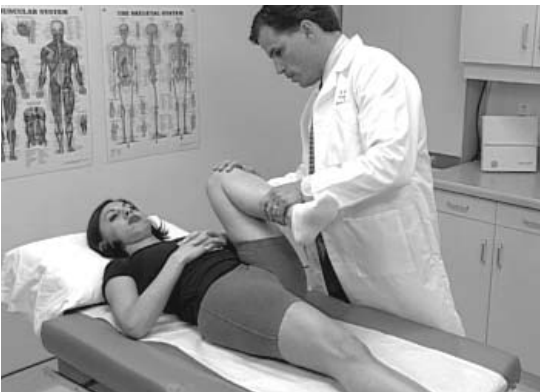
Figure 43. Hip flexion and extension.

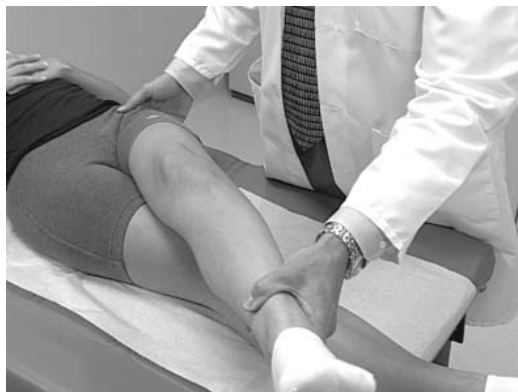
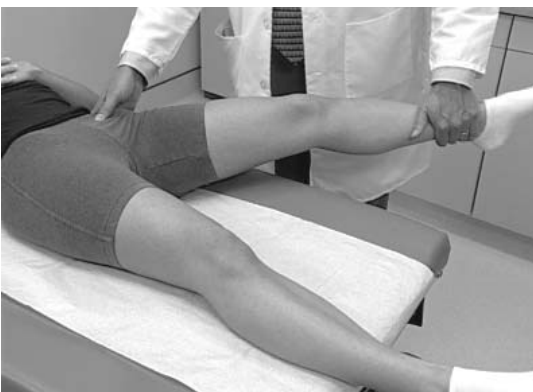
Figure 44. Hip abduction and adduction.

Strength Testing

Strength should be evaluated by resisting range of motion:

1. Extension strength — while prone, raise entire leg from table (gluteus maximus and hamstrings).
2. Flexion strength — while seated, flex hip upward against resistance (iliopsoas, rectus femoris and sartorius). (Figure 45)
3. Adduction strength — while supine, resist attempts to push feet together (gluteus medius and minimus).
4. Abduction strength — while supine, resist attempts to pull feet apart (adductors longus/brevis/magnus and gracilis). (Figure 45)

Sensory

Evaluate sensation about the hip in the following areas:

1. Distal lateral thigh — hypesthesia here may indicate meralgia paresthetica, caused by compression of the lateral femoral cutaneous nerve.
2. Obturator nerve — innervates hip as well as medial thigh and knee (may cause pain from hip pathology to be felt in knee).

Special Tests

Evaluate the hip using the following special tests:

1. Trendelenburg test — while standing on one foot, look for pelvic tilt toward raised foot. Indicates weak hip abductor muscles (Figure 46).
2. Hop test — stand or hop unsupported on one leg. Look for reproduced pain at groin area. This test is usually positive with a femoral neck stress fracture.
3. Leg length — should be measured from the anterior superior iliac spine (ASIS) to the medial malleolus and compared to opposite side. X-ray to confirm a suspected discrepancy.

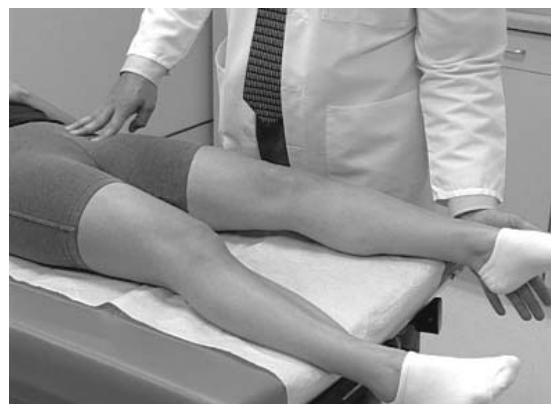
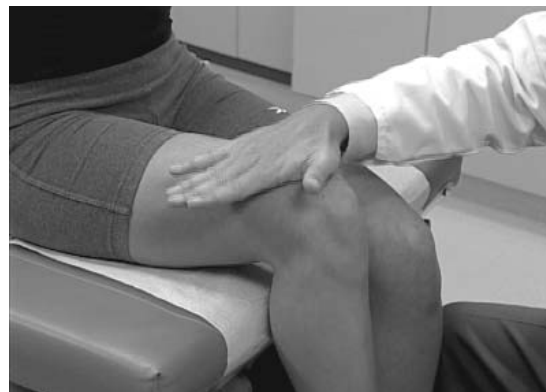
Figure 45. Checking for hip flexion and abduction strength.

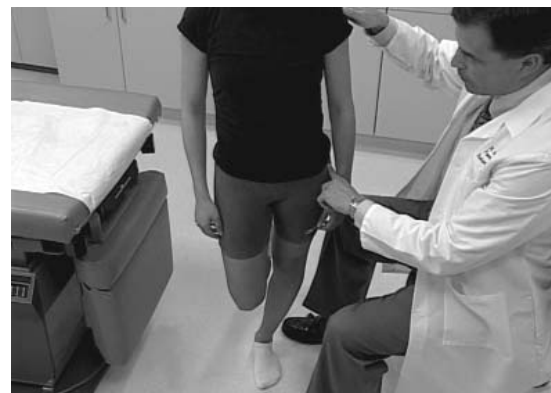


Figure 46. Trendelenburg test for hip abductor weakness.

4. Log roll test — severe pain with gentle to-and-fro motion of pelvis may indicate fracture, infection or synovitis (*Figure 47*).
5. FABER test — performed while supine, with ankle placed on top of the opposite knee in the figure-4 position. Discomfort is often seen with SI joint pathology (*see Figure 40, p.44*).
6. Ober's test — lie on side with upper knee flexed to 90° (*Figure 48*). Measure distance of flexed knee from table. Inability to bring knee down to table suggests iliotibial (IT) band tightness, which can predispose to the IT band friction syndrome.

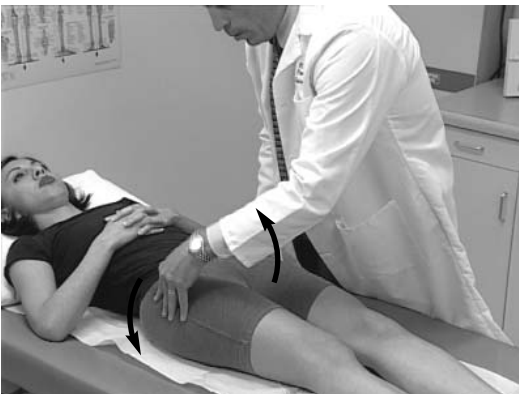

Figure 47. Log roll test.

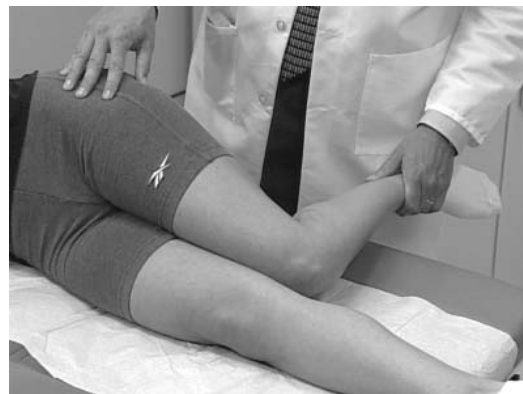

Figure 48. Ober's test for iliotibial band tightness.

Hip Exam Landmarks

The following anatomic landmarks should be located:

Anterior Hip Joint

Iliac Crests (L4 spinal level)

Anterior Superior Iliac Spine

Anterior Inferior Iliac Spine

Greater Trochanter

Iliotibial Band

Gluteus Muscle

Posterior Superior Iliac Spine

Sacroiliac Joints

Sciatic Notch

Ischeal Tuberosity

Hamstring Muscles

Hip Exam Essentials

- ___ 1. **Inspect** both hips from front and back. Observe gait up and down the hall.
- ___ 2. **Palpate** the hip for areas of tenderness.
 - A. Anterior hip joint
 - B. Anterior superior/inferior iliac spine
 - C. Greater trochanter
 - D. Iliotibial band
 - E. Gluteus muscle
 - F. SI joint
- ___ 3. **Range of motion** is tested while looking for pain or limitation.
 - A. Internal rotation (30°) — stabilize knee at 90° flexion with patient seated and move foot away from midline
 - B. External rotation (60°) — move foot toward midline
 - C. Flexion (120°) — with patient supine, grasp bent knee and pull to chest (stop when back flattens)
 - D. Hyperextension (15°) — while prone, lift leg off table
 - E. Abduction (45°) — with patient supine, hold ankle and pull leg away from midline
 - F. Adduction (30°) — with patient supine, pull leg toward midline (until pelvis tilts)
- ___ 4. **Strength testing** is performed by resisted range of motion.
 - A. Flexion strength — while seated, flex hip upward against resistance
 - B. Adductor strength — while supine, resist attempts to push feet together
 - C. Abductor strength — while supine, resist attempts to pull feet apart
 - D. Extension — while prone, raise entire leg from table
- ___ 5. **Sensory**
 - A. Distal lateral thigh — hypesthesia here may indicate meralgia paresthetica
 - B. Obturator nerve — innervates hip as well as medial thigh and knee
- ___ 6. **Special tests**
 - A. Trendelenburg test — while standing on one foot, look for pelvic tilt toward raised foot
 - B. Ober's test — lie on side with upper knee flexed to 90°, measure distance of flexed knee from table for IT band tightness
 - C. Hop test — hop unsupported on one leg. Look for reproduced pain at groin area (with femoral neck stress fracture)
 - D. Log roll test — severe pain with gentle to-and-fro motion of pelvis (may indicate fracture, infection or synovitis)
 - E. Leg length — should be measured from the ASIS to the medial malleolus

Knee Evaluation

Knee Exam Landmarks

Knee Exam Essentials

KNEE EVALUATION

HISTORY

The evaluation of the patient with a knee problem begins with a detailed history. Essential questions include:

What was the mechanism of injury?

Picturing forces applied to the knee during the injury can be helpful in determining what structures were injured (*Table 1, page 65*). The “two fist sign,” in which the patient describes injury by opposing both fists with a twisting motion, is highly predictive of anterior cruciate ligament (ACL) tear.

Did you hear or feel a pop?

The presence of a pop in the knee, when associated with a twisting injury, is a very significant symptom. This is most suggestive of an ACL tear (~80% chance), meniscal tear (~15%) or possibly a fracture.

Where was the pain located?

The location of pain at the time of injury can also suggest which structures might be injured (*Figure 49*).

1. Medial — medial collateral ligament (MCL), meniscus, pes anserine.
2. Lateral — meniscus, IT Band, lateral collateral ligament (LCL), postero-lateral corner.
3. Front — patella, ACL (deep), patellar tendon, quad tendons.
4. Back — Hamstring tendons, posterior cruciate ligament (PCL), Baker’s cyst.

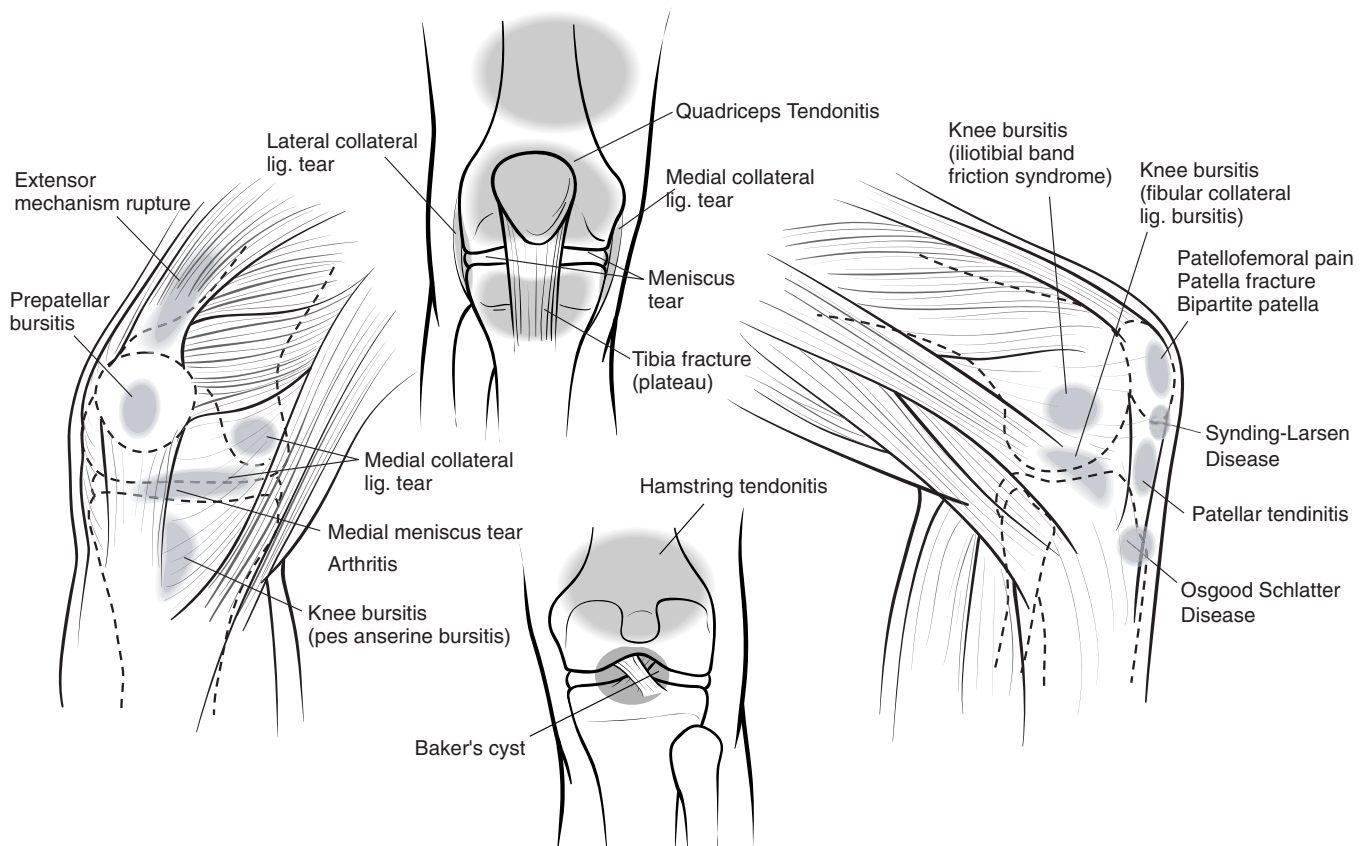


Figure 49. Locations of common causes of knee pain.

Were you able to continue the sport or other activity?

It is unlikely a patient will continue playing a sport or other physical activity if they have suffered a serious ligament or cartilage injury. Patients with an ACL injury may try, but invariably stop because the knee feels unstable. Generally, an MCL injury feels fine when walking or running straight ahead, but hurts when moving laterally.

How long until swelling occurred?

The length of time between when an injury occurs and when swelling is first noticed can be helpful diagnostically. Swelling occurring within 24 hours of injury is usually blood (aspiration may be used to confirm this or to relieve associated discomfort).

1. 0 – 12 hours — suspect ACL tear or patella dislocation.
2. 12 – 24 hours — suspect meniscal tear.
3. Recurring — suspect chronic or degenerative meniscal tear or OA.

What treatments were used after the injury?

Asking if proper treatment was used immediately after the injury can be a helpful gauge of injury severity. If RICE (rest, ice, compression, elevation) was used and the knee is still swollen and sore, significant injury is more likely. Likewise, if range of motion and therapy exercises have been performed since the injury and the knee remains stiff or the quads appear atrophied, significant injury is more likely.

Are there any mechanical symptoms since the injury?

Mechanical symptoms in the knee refer to swelling, locking or giving way. The presence of these symptoms suggests a meniscal tear. Locking is the inability to fully extend the knee.

Is there a history of prior knee problems?

Prior knee injury can predispose to future problems. The natural history of an ACL-deficient knee is to develop a meniscal tear and eventually osteoarthritis. A healed or repaired meniscal tear is at risk to re-tear and a patella dislocation at risk to recur.

EXAMINATION

Both legs should be exposed from the thigh down when examining the knee to compare the uninvolved knee. Important aspects of the knee exam include:

Inspection

Carefully compare both knees looking for:

1. Swelling or effusion — see below.
2. Ecchymosis — evidence of trauma.
3. Quad atrophy — suspect significant internal derangement.

Palpate for Effusion

Swelling in front of the kneecap suggests pre-patellar bursitis or infection, while swelling behind the kneecap suggests knee joint effusion and likely significant internal derangement. The amount of swelling has some diagnostic significance and can be roughly graded from 0 to 3+:

1. 0 (no effusion) — a normal knee joint has no effusion.

2. 1+ (trace effusion) — think OA or old meniscal tear.
3. 2+ (moderate effusion) — think acute meniscal tear or PCL tear.
4. 3+ (large effusion) — think ACL tear or patellar dislocation.

Palpate for Tenderness

Important areas to palpate include (Figure 50):

1. Tibial tubercle (Osgood Schlatter).
2. Patella tendon (tendinitis).
3. Medial and lateral divots — palpable divots can be felt on either side of the patella tendon (represent the anterior most part of the joint line).
4. Patella — around (patellofemoral pain), over (pre-patella bursitis) and under (chondral injury). Pain at the inferior pole of the patella suggests Synding-Larsen disease (patella apophysitis).
5. Joint line — medial/lateral and anterior/posterior (meniscal tear). Start at medial and lateral divots and work your way to the back of the knee.
6. Medial side (MCL, pes anserine bursa).
7. Lateral side (LCL, IT band).

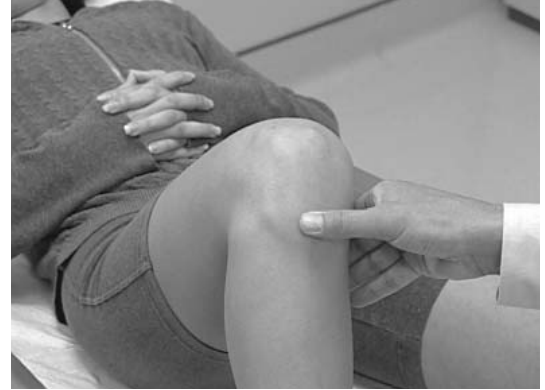

Figure 50. Palpating the knee for tenderness.

Range of Motion

The range of motion of the knee joint is generally assessed passively, with the patient lying supine. The knee should be checked for the following motions:

1. Extension (0° normal) — a lack of knee extension suggests mechanical block (ie, torn meniscus, loose body or large effusion). This is most accurately assessed by lying the patient prone and measuring the difference in heel height to detect a more subtle lack of extension (Figure 51).
2. Flexion (130° normal) — can be limited by joint effusion or quadriceps spasm.
3. Extensor mechanism — it is essential to check for active knee extension to assess the integrity of the extensor mechanism (quadriceps muscle and tendon, patella, patella tendon and tibial tubercle). (Figure 52)
4. Crepitus — is rarely significant unless associated with significant pain, effusion or limitation of motion.

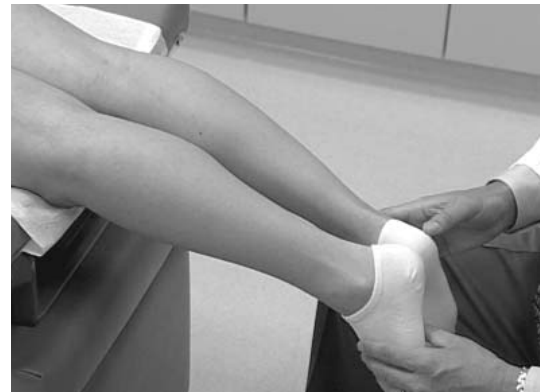

Figure 51. Measuring heel height difference, with patient prone, to detect a lack of extension.

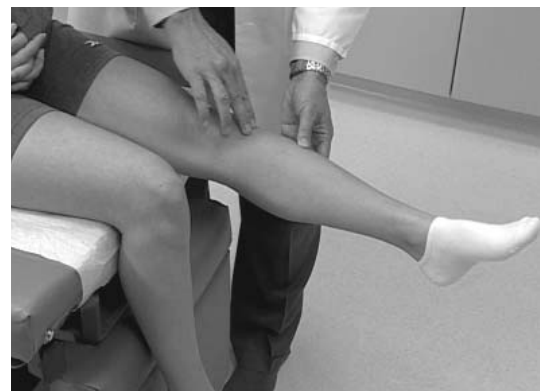

Figure 52. Checking for active extension to evaluate the extensor mechanism.

Ligament Testing

The following knee ligaments should be evaluated:

1. MCL — test by exerting a valgus stress on the knee with it extended and then flexed to 20°. Three grades of injury are described:
 - A. Grade I — pain without laxity.
 - B. Grade II — pain with slight laxity (weak end point).
 - C. Grade III — less pain with significant laxity (no good end point).
 - D. Laxity to valgus stress applied with the knee in full extension suggests injury to the ACL and/or PCL, as well as the MCL (Figure 53). The ACL and PCL are taut when the knee is in full extension and should act to prevent valgus laxity in this position. Bending the knee to 20° loosens these ligaments and allows isolated testing of the MCL.
2. LCL — test by exerting a varus stress, also with the knee extended and then flexed to 20°. The LCL is much less commonly injured than the MCL. The same grading that is used for MCL injury can be used to describe injury to the LCL. If significant laxity to varus stress is noted, suspect more serious injury to the posterolateral corner of the knee. Such an injury may accompany a knee dislocation and warrants urgent orthopedic referral.
3. ACL — three tests are commonly used to evaluate the ACL:
 - A. Lachman test — performed with knee in 20° of flexion and applying an anteriorly directed force on the tibia while stabilizing the thigh (Figure 54). This is the definitive exam to evaluate for ACL tear.
 - B. Anterior drawer test — performed with knee in 90° of flexion and foot flat on table by pulling the tibia anterior (Figure 55). The sensitivity of this exam is limited because with the knee flexed to 90° the collateral ligaments are taut and restrain anterior motion.
 - C. Pivot shift — performed with the leg internally rotated by flexing the knee past 20° while applying a slight valgus stress and looking for the tibia to shift backward. This test is helpful in assessing the secondary restraints of the knee joint, and will usually only be positive when the knee is very lax after an ACL tear. This test is often painful, which limits its usefulness (not shown on video).

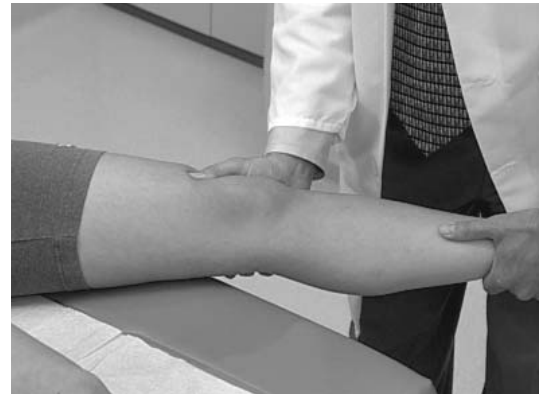

Figure 53. Assessing the MCL with the knee in full extension by applying a valgus stress.

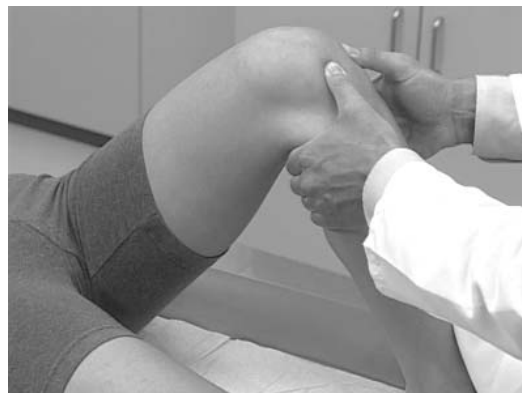
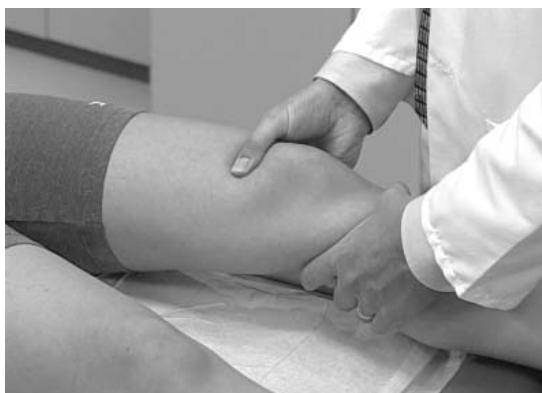
Figure 54. Lachman test for ACL laxity. Figure 55. Anterior drawer test for ACL.

4. PCL – two tests are commonly performed to evaluate the PCL:
- Posterior drawer test – also performed with knee in 90° of flexion by pushing the tibia posterior (*Figure 56*). Significant posterior displacement of the tibia suggests a PCL injury.
 - Sag sign – performed with both knees flexed to 90° and feet flat on exam table (*Figure 57*). A posterior directed tibial sag on the involved knee suggests a PCL tear with significant posterior laxity.

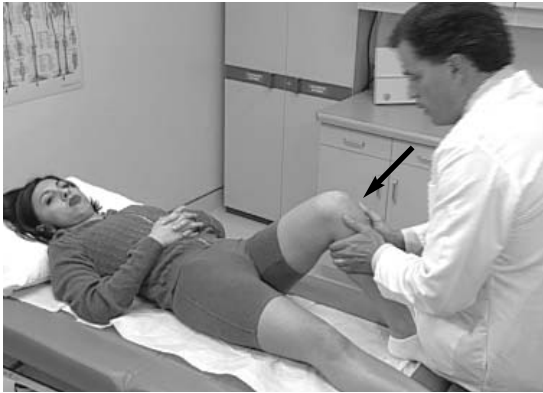

Figure 56. Posterior drawer test for PCL.

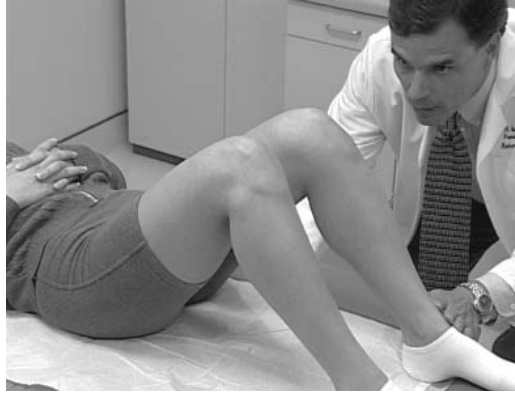

Figure 57. Checking for the sag sign indicating PCL laxity.

Meniscal Tests

The tests performed to evaluate for meniscal injury are often nonspecific with a high rate of false positives. The most common meniscal tests described include:

- Bounce test — performed with the patient lying supine by bouncing the knee into full extension. An injured meniscus will cause significant pain as it gets pinched with knee extension.
- Joint line tenderness — palpable tenderness over the meniscus at the medial or lateral joint line suggests injury to this structure.
- Prone knee extension — while lying the patient prone with both knees hanging just off the end of the exam table, look for a difference in heel height. This may indicate a mechanical block to knee extension caused by a torn and displaced meniscus (*Figure 51, p. 61*).
- Duck walk — performed by getting into a full squat and walking in the squatted position (*Figure 58*). A patient is unlikely to have a significant cartilage or ligament injury if they are able to do this.
- McMurray's test — performed by flexing and extending the knee, combined with internal and external rotation. A significant clunk with this maneuver may indicate a displaced meniscal tear. This test should be performed with caution as one may cause a torn meniscus to displace and lock the knee joint. The usefulness of this test is limited by its high rate of false-positives (not shown on video).
- Apley compression test — performed with the knee bent to 90° while lying prone on the exam table. Watch for a significant clunk during knee flexion and extension while applying an axial load in both internal and external rotation. This test is also limited by a high false-positive rate (not shown on video).

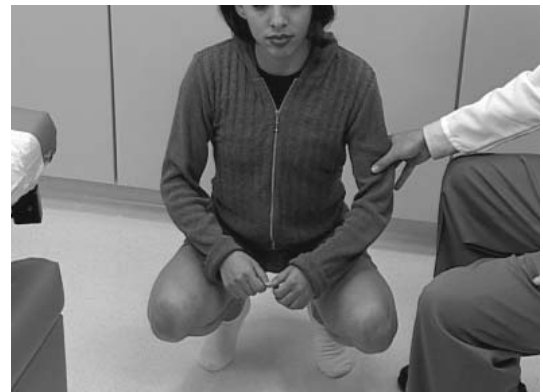

Figure 58. Duck walk test.

Patella Tests

Several tests can be performed to evaluate for patellofemoral dysfunction or dislocation:

1. Patella apprehension test – performed by pushing the kneecap in a lateral direction with the patient lying supine. The test is positive when the patient becomes apprehensive that the patella may recurrently dislocate. This suggests a recent patella dislocation (*Figure 59*).
2. Patella grind test – with the patient lying supine, pushing down on the kneecap and grinding back and forth can aggravate the pain of patellofemoral dysfunction. This test also has a very high false-positive rate (*Figure 59*).
3. Q-angle (quadriceps angle) – the angle formed by a line connecting the ASIS of the hip and the center of the patella, with a line down the anterior tibia. Angles greater than 10° in male and 15° in female may predispose to patellofemoral problems. The wider pelvis seen in women increases their Q-angle and has been thought to contribute to their increased incidence of patellofemoral pain.

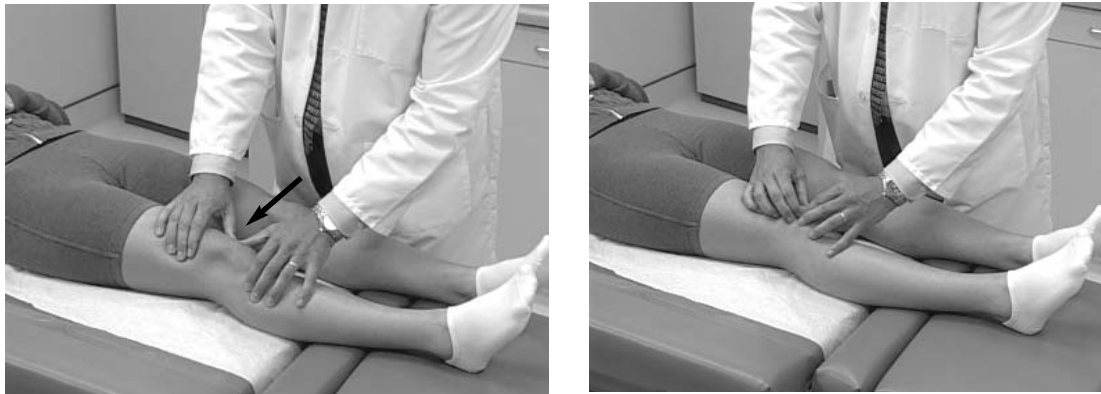

Figure 59. Patella apprehension and grind tests.

TABLE 1

FORCES THAT INJURE THE KNEE

(Summary)

1. Valgus Force

- A. MCL (or physeal fracture)
- B. ACL
- C. Medial Meniscus

2. Varus Force

- A. LCL (or physeal fracture)
- B. ACL
- C. Lateral Meniscus

3. Anterior Drawer (anterior directed force with knee bent)

- A. Isolated Anterior Cruciate Ligament

4. Posterior Drawer (posterior directed force with knee bent)

- A. Isolated Posterior Cruciate Ligament

5. Internal Rotation Force

- A. ACL
- B. LCL

6. External Rotation Force

- A. ACL
- B. MCL
- C. Patellar Dislocation

7. Hyperextension

- A. ACL
- B. PCL
- C. Knee dislocation with potential for tearing all ligaments, cartilage and even neurovascular injury

Knee Exam Landmarks

The following anatomic landmarks should be located:

Palpate with knee flexed to 90° and foot flat on table

Tibial Tubercle

Patella Tendon

Patella

Medial & Lateral Divots (either side of patella tendon)

Medial Joint Line

Lateral Joint Line

Head of Fibula

Medial Femoral Condyle

Lateral Femoral Condyle

Medial Collateral Ligament

Lateral Collateral Ligament

Iliotibial Band

Pes Anserinus

Knee Exam Essentials

- ___ 1. **Inspect** the knees for evidence of swelling, ecchymosis or atrophy.
- ___ 2. **Palpate** for swelling or joint **effusion** as well as **warmth**.
- ___ 3. **Palpate** for areas of tenderness. Should specifically palpate these areas:
 - A. Tibial tubercle
 - B. Medial and lateral divots
 - C. Patella (medial, lateral, tendon)
 - D. Quadriceps tendons
 - E. Joint line (medial/lateral and anterior/posterior)
 - F. Ligaments (MCL/LCL)
- ___ 4. **Range of motion** testing should include both active and passive.
 - A. Extension (0°) – also check heel height difference while lying prone
 - B. Flexion (130°)
 - C. Palpation over knee for crepitus
 - D. Assess extensor mechanism (by checking for active extension of knee)
- ___ 5. **Ligament** testing should be performed for evidence of pain or laxity.
 - A. MCL — Valgus stress at 0° and 20° to 30° flexion
 - B. LCL — Varus stress at 0° and 20° to 30° flexion
 - C. ACL — Lachman’s test (20° flexion); Anterior drawer test (90° flexion); Pivot shift (optional)
 - D. PCL — Sag sign (90° flexion); Posterior drawer test (90° flexion)
- ___ 6. **Meniscal** tests — look for pain, locking or a decreased range of motion.

**Note: All these tests have high rate of false-positives.*

 - A. Prone knee extension (observe for lack of extension)
 - B. Bounce test
 - C. Apley compression test (optional)
 - D. McMurray’s test (optional)
 - E. Duck walk
- ___ 7. **Patella** tests reveal evidence of patellofemoral dysfunction.
 - A. Apprehension test
 - B. Patellar grind test
 - C. Q-angle

Ankle Evaluation

Ankle Exam Landmarks

Ankle Exam Essentials

ANKLE EVALUATION

HISTORY

Evaluation of the patient with an ankle problem should begin with a good history. Important questions include:

What was the mechanism of injury or overuse?

The ankle can be injured by repetitive overuse (such as with running) or an acute injury. The most common mechanisms for ankle injury include:

1. Inversion — this is the most common way to injure the ankle and typically occurs after stepping wrong and rolling the ankle into inversion. This will injure the lateral ankle ligaments, and when combined with plantar-flexion can injure the peroneal tendon.
2. Eversion — the opposite mechanism to inversion can injure the medial ankle ligament (deltoid ligament). Combined eversion and external rotation can dislocate the peroneal tendon.
3. External rotation — when applied forcefully can injure the ankle syndesmosis (tibiofibular ligament).
4. Dorsiflexion — a sudden dorsiflexion caused by landing after a jump can injure the achilles tendon. Very forceful dorsiflexion at the ankle can also injure the ankle syndesmosis.
5. Plantar-flexion — against resistance, caused by forceful gastro-soleus contraction, can tear the achilles tendon. Forcing the ankle into extreme plantar flexion can dislocate the ankle joint.

Did you hear or feel a pop?

A pop at the lateral or medial ankle suggests a ligament tear, while a pop at the back of the ankle suggests achilles tendon rupture. Recurrent lateral ankle popping is suggestive of peroneal tendon subluxation.

Were you able to bear weight after the injury? Continue playing?

The answer to these questions are helpful in assessing the severity of injury to the ankle. The inability to bear weight is a sign of increased fracture risk and need for x-ray. The **Ottawa ankle rules** (*Figure 60*) can be useful in deciding when to order an x-ray in a patient with an ankle injury. In general, an ankle x-ray should be ordered if:

1. There is tenderness to palpation along the lower 6 cm of the posterior border of either the medial or lateral malleolus.
2. The patient is unable to bear weight both immediately following the injury and on presentation due to pain in the ankle.
3. Foot x-rays should be obtained if there is significant tenderness at the proximal 5th metatarsal or over the tarsal navicular bone.

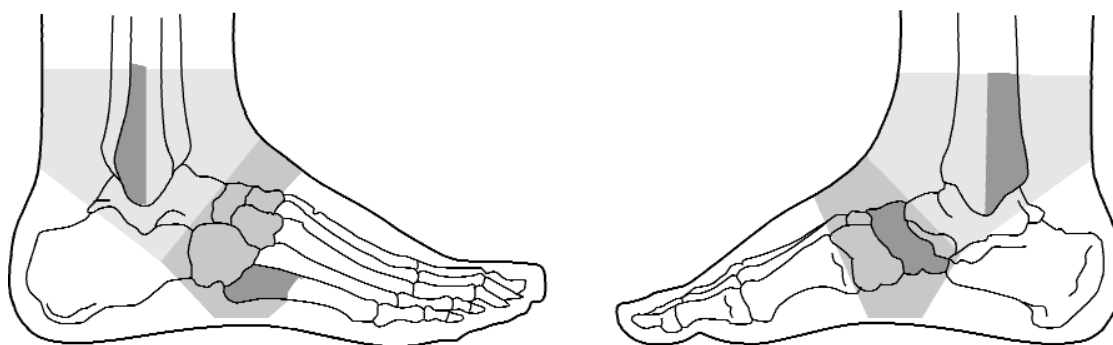


Figure 60. Locations of tenderness with Ottawa ankle rules.

Was there associated swelling or ecchymosis?

Swelling and bruising suggest ligament or tendon rupture. The initial location of swelling or bruising can be helpful in localizing injured structures. Over time, swelling and bruising associated with ankle injury sinks to the foot and is reabsorbed.

Where was the pain located?

The location of pain in the ankle can be helpful diagnostically (Figure 61). Localizing the pain to medial, lateral, anterior or posterior can suggest the injured structure.

1. Lateral — anterior talofibular ligament, calcaneofibular ligament, posterior talofibular ligament, peroneal tendon, lateral malleolus.
2. Medial — deltoid ligament, tibialis posterior tendon, medial malleolus.
3. Posterior — achilles tendon, OS trigonum.
4. Anterior — talus, tibiotalar joint.

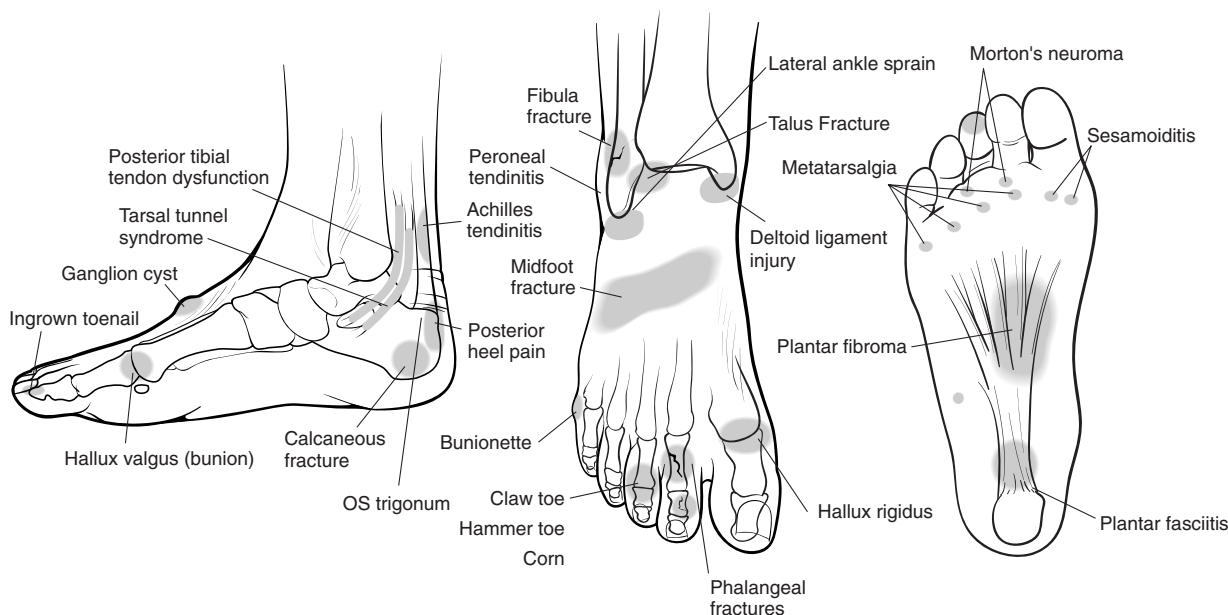


Figure 61. Location of common causes of ankle and foot pain.

What treatments were used after the injury?

If RICE (rest, ice, compression, elevation) was used after the injury and the ankle is still very swollen, a significant injury is more likely.

Has there been persistent pain and/or swelling since the initial injury?

The most common reason for persistent symptoms after an ankle injury is inadequate or incorrect treatment. This could also indicate an underlying fracture, cartilage injury or ligament injury.

EXAMINATION

The ankle, along with the lower leg and foot should be exposed on both sides to compare for differences. Important parts of the ankle exam include:

Inspection

Inspect and compare both fully exposed ankles from the front, the side and from behind. Look for asymmetry as well as arch deformities, swelling or ecchymosis. You should also look at shoes for abnormal wear patterns.

Palpation

Palpate the lower leg, ankle and foot in the following areas of tenderness:

1. Lower leg: fibula, interosseous membrane, anterior compartment, anterior ankle joint line.
2. Medial ankle: medial malleolus, deltoid ligament, tibialis posterior tendon.
3. Lateral ankle: lateral malleolus, anterior talofibular ligament (ATFL), calcaneofibular ligament (CFL), posterior talofibular ligament (PTFL), peroneal tendon (*Figure 62*).
4. Posterior ankle: achilles tendon, calcaneus.
5. Foot: proximal 5th metatarsal, navicular.



Figure 62. Palpating the lateral ankle for tenderness.

Range of Motion

Ankle motion should first be assessed actively and then passively, comparing both ankles to look for asymmetry. Check for limited motion and/or pain.

1. Dorsiflexion normally about 20° (*Figure 63*)
2. Plantar flexion about 50°
3. Inversion about 30°
4. Eversion about 10°

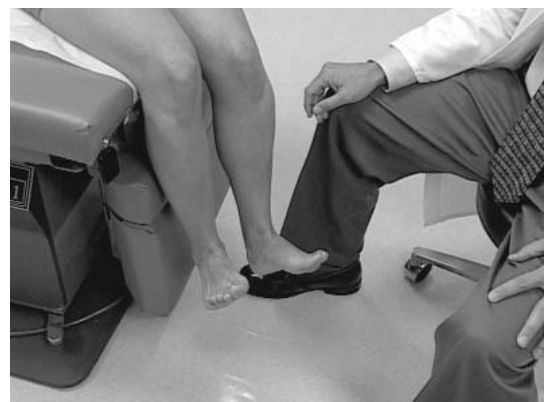

Figure 63. Checking ankle dorsiflexion motion.

Strength Testing

Check for muscle weakness and/or pain. This is performed by resisted ankle movements.

1. Resisted dorsiflexion (tibialis anterior). (*Figure 64*)
2. Resisted plantar-flexion (gastroc, peroneal longus, tibialis posterior).
3. Resisted eversion (peroneal longus and brevis).
4. Resisted inversion (tibialis posterior, tibialis anterior). (*Figure 64*)

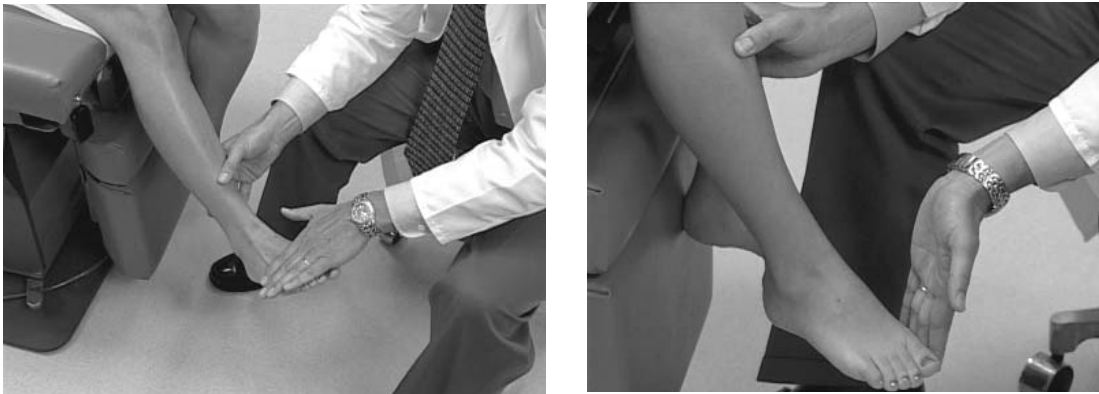

Figure 64. Testing ankle dorsiflexion and inversion strength.

Special Tests

A variety of tests can be performed on the ankle to assess integrity of the ankle ligaments and tendons. When doing these tests, check for evidence of laxity and/or pain.

1. Anterior drawer test — performed by stabilizing the lower leg with one hand while cupping the heel with the other, then pulling forward on the calcaneus/talus complex (*Figure 65*). Laxity compared to the uninvolved side suggests lateral ligament rupture.
2. Talar tilt test — performed by similarly stabilizing the lower leg with one hand while cupping the heel with the other, then inverting the ankle joint. Inversion laxity compared to the uninvolved side suggests tearing of the lateral ligaments, while pain with this maneuver suggests ligament injury.
3. Squeeze test — performed by squeezing the proximal tibia and fibula together while asking about pain distally at the ankle (*Figure 66*). Pain in the ankle suggests injury to the tibiofibular ligament (syndesmosis sprain). Passively rotating the ankle into external rotation will also aggravate pain from a syndesmosis injury.



Figure 65. Anterior drawer test for lateral ankle ligament laxity.



Figure 66. Squeeze test for syndesmosis injury.

4. Thompson test — performed by squeezing at the base of the calf muscle and looking for ankle plantar-flexion (*Figure 67*). A lack of plantar flexion suggests a complete achilles tendon rupture.

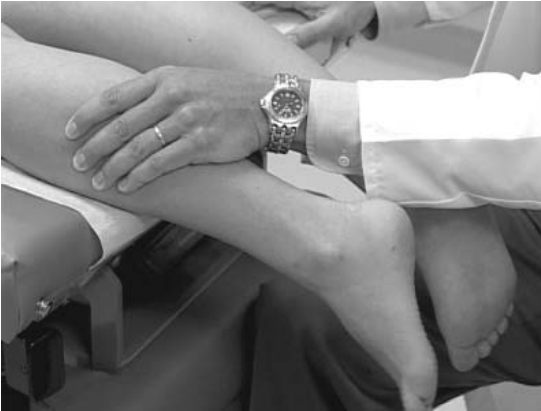

Figure 67. Thompson test for complete achilles tendon rupture.

Functional Tests

These sequential activities are performed to see if they cause pain or other symptoms. This can be helpful in advising return to play or activity.

1. Walking
2. Standing/walking on toes/heels
3. Squatting
4. Jogging
5. Running straight ahead
6. Running and cutting

Ankle Exam Landmarks

The following anatomic landmarks should be located:

Ankle Joint Line

Anterior Talofibular Ligament

Calcaneofibular Ligament

Posterior Talofibular Ligament

Deltoid Ligament

Tip and Posterior Edge of Medial Malleolus

Tibialis Posterior Tendon

Tip and Posterior Edge of Lateral Malleolus

Peroneal Tendon

Achilles Tendon

Base of the 5th Metatarsal

Navicular bone of foot

Ankle Exam Essentials

- ___ 1. **Inspect** and compare both fully exposed ankles from the front, the side and from behind. Look for arch deformities, swelling or ecchymosis. Also note appearance of shoes.

- ___ 2. **Palpate** the lower leg, ankle and foot for areas of tenderness.
 - A. Lower leg: fibula, interosseous membrane, anterior compartment
 - B. Medial ankle: medial malleolus, deltoid ligament, tibialis posterior tendon
 - C. Lateral ankle: lateral malleolus, ATFL, CFL, PTFL, peroneal tendon
 - D. Posterior ankle: achilles tendon
 - E. Foot: proximal 5th metatarsal, navicular

- ___ 3. **Range of motion** should be performed first actively and then passively if needed, while comparing both ankles.
 - A. Dorsiflexion 20°
 - B. Plantar flexion 50°
 - C. Inversion 30°
 - D. Eversion 10°

- ___ 4. **Strength testing** should look for muscle weakness and/or pain. It is performed as resisted ankle movements.
 - A. Resisted dorsiflexion (tibialis anterior)
 - B. Resisted plantar-flexion (gastroc, peroneal longus, tibialis posterior)
 - C. Resisted inversion (tibialis posterior, tibialis anterior)
 - D. Resisted eversion (peroneal longus brevis)

- ___ 5. **Stability testing** is performed to assess the integrity of the ankle ligaments. Check for evidence of laxity and/or pain.
 - A. Talar tilt test
 - B. Anterior drawer test
 - C. Squeeze test (for syndesmotic sprains)
 - D. Thompson test (for achilles tendon ruptures)

- ___ 6. **Functional tests** are performed to see whether these sequential activities produce pain or other symptoms.
 - A. Squatting
 - B. Standing/walking on toes/heels
 - C. Jogging
 - D. Running straight ahead
 - E. Running and cutting

References

Acknowledgements

Self-assessment Questions

REFERENCES

1. Adkins SB III, Figler RA. Hip pain in athletes. *Am Fam Physician*. 2000;61:2109-18.
2. Bach AW. Finger joint injuries in active patients: pointers for acute and late-phase management. *Physician Sportsmed*. 1999;27:89.
3. Birnbaum, JS. *The Musculoskeletal Manual*. 2d ed. Orlando, Fl.: Grune and Stratton; 1986.
4. Chumbley EM, O'Conner FG, Nirschl RP. Evaluation of overuse elbow injuries. *Am Fam Physician*. 2000;61:691-700.
5. Greene WB, American Academy of Orthopaedic Surgeons, American Academy of Pediatrics. *Essentials of Musculoskeletal Care*. 2d ed. Rosemont, Ill.: American Academy of Orthopaedic Surgeons; 2001.
6. Hockenbury TR, Sammarco GJ. Evaluation and treatment of ankle sprains: clinical recommendations for a positive outcome. *Physician Sportsmed*. 2001;29:57.
7. Honing EW. Wrist injuries. *Physician Sportsmed*. 1998;26:40.
8. Patel AT, Ogle AA. Diagnosis and management of acute low back pain. *Am Fam Physician*. 2000;61:1779-86,1789-90.
9. Reider B. *The Orthopedic Physical Exam*. Philadelphia, Pa.: WB Saunders: 1999.
10. Rubin AL, Sallis RE. Evaluation and diagnosis of ankle injuries. *Am Fam Physician*. 1996;54:1609-18.
11. Smith BW, Green GA. Acute knee injuries: Part II. Diagnosis and management. *Am Fam Physician*. 1995;51:799-806.
12. Woodward TW, Best TM. The painful shoulder: part I. Clinical evaluation. *Am Fam Physician*. 2000;61:3079-88.

Acknowledgements

I would like to thank the sports medicine fellows at Kaiser Permanente in Fontana: Cher Cohler, MD, Eric Hooper, MD, and Jared Williams for their help with question writing and review of the manuscript.

I would also like to thank Ana Lara, PA for serving as the model in the videotapes. Her input during filming was invaluable.

Finally, I would like to thank Rick Tilley and the Kaiser Permanente Multimedia Communications department for their help with filming and editing of the videotapes.

Examination of the Musculoskeletal System

Self-study Program

Self-assessment Questions

1. The “drop arm test”, when positive, suggests?
 - a. Clavicle fracture
 - b. AC joint separation
 - c. Large rotator cuff tear or nerve injury
 - d. Biceps tendinitis
2. The cross-over test, when positive, may suggest?
 - a. AC joint pain
 - b. Glenohumeral joint instability
 - c. Impingement syndrome
 - d. Both a and c
3. Glenohumeral instability is commonly seen in?
 - a. Young, active patients
 - b. Elderly
 - c. Young, sedentary patients
 - d. Pregnancy
4. Characteristics of rotator cuff tendinitis include?
 - a. Pain that improves with activity and worsens with rest
 - b. Pain located in the bicipital groove
 - c. Pain that improves with rest and worsens with activity
 - d. Pain related to trauma
5. Abduction with thumbs down and 30° horizontal adduction (“empty can test”) isolates which rotator cuff muscle?
 - a. Subscapularis
 - b. Teres minor
 - c. Supraspinatus
 - d. Infraspinatus
6. Loss of both active and passive shoulder motion may suggest which of the following?
 - a. Labrum tear
 - b. Adhesive capsulitis
 - c. Severe impingement
 - d. All of the above
7. When performing Neer’s test, pain or lack of motion is commonly seen with?
 - a. Impingement syndrome
 - b. AC separation
 - c. Glenohumeral instability
 - d. Labrum tear
8. A positive Spurling’s test (radicular pain to the shoulder and arm during axial loading to the top of the head with the neck twisted) may represent?
 - a. Cervical nerve root irritation
 - b. Deltoid atrophy
 - c. Impingement syndrome
 - d. Muscle spasm

9. A common source of radicular pain to the shoulder is?
 - a. Wrist
 - b. Hip
 - c. Thoracic spine
 - d. Cervical spine
10. Resisted extension and supination of the wrist tends to aggravate?
 - a. Medial epicondylitis
 - b. Ulnar nerve subluxation
 - c. Lateral epicondylitis
 - d. Olecranon bursitis
11. A sudden painful pop at the medial elbow while throwing may indicate?
 - a. Osteoarthritis of the elbow
 - b. Epicondylitis
 - c. Ulnar collateral ligament tear
 - d. Carpal tunnel syndrome
12. Recurrent popping at the medial elbow associated with tingling to the 4th and 5th finger may indicate?
 - a. Ulnar nerve subluxation
 - b. Ulnar collateral ligament tear
 - c. Arthritis
 - d. Carpal tunnel syndrome
13. Severe night pain in the shoulder that prevents sleep suggests?
 - a. Rotator cuff tear
 - b. Biceps tendinitis
 - c. Glenohumeral instability
 - d. AC separation
14. Shoulder muscle asymmetry may indicate which of the following?
 - a. Rotator cuff tear
 - b. Nerve injury
 - c. Adaptive hypertrophy
 - d. All of the above
15. A snapping sound in the wrist usually represents?
 - a. Synovitis
 - b. Carpal tunnel syndrome
 - c. Subluxing tendons
 - d. Infection
16. Which nerve is being tested when the hand is placed on a flat surface, palm up and the thumb is raised against resistance?
 - a. Radial
 - b. Median
 - c. Ulnar
 - d. None of the above
17. The inability to flex the DIP joint is suggestive of?
 - a. Ulnar collateral ligament tear
 - b. Mallet finger
 - c. Jersey finger
 - d. deQuervain's tendinitis
18. When testing range of motion of the back, forward flexion most increases?
 - a. Facet pain
 - b. Muscular pain
 - c. Tendon pain
 - d. Disc pain

19. Weakness with resisted great toe dorsiflexion is suggestive of irritation of which nerve root?
- S1
 - L5
 - L4
 - L3
20. The Stork test will aggravate pain associated with?
- Spondylolysis
 - Spondylolisthesis
 - SI joint dysfunction
 - All of the above
21. Pain with the FABER test is suggestive of?
- SI joint pathology
 - Sciatica
 - IT band tightness
 - Synovitis
22. Which test is usually positive with a femoral neck stress fracture?
- Hop test
 - Log roll test
 - Ober's test
 - Trendelenburg test
23. Pain from sciatica worsens with which maneuver?
- Extension of back
 - Flexing knee
 - Twisting of back
 - Valsalva
24. Which test when positive is suggestive of deQuervain's tendinitis?
- Watson stress test
 - Grind test
 - Tinel's test
 - Finkelstein's test
25. The presence of locking of the knee suggests what injury?
- Patellofemoral syndrome
 - MCL tear
 - Quadriceps strain
 - Meniscal tear
26. This is the most common injury to the ankle:
- Inversion injury
 - Eversion injury
 - Dorsiflexion
 - External rotation
27. A large (3+) effusion of the knee occurring within 12 hours of an injury suggests which of the following?
- ACL tear
 - Osgood-Schlatter's disease
 - Patellofemoral syndrome
 - LCL sprain
28. Pain over the tibia tubercle is an important exam finding in which of the following?
- Meniscal tears
 - MCL sprain
 - Bipartate Patella
 - Osgood-Schlatter's disease

29. What is the typical mechanism for injury to the deltoid ligament of the ankle?
- Ankle inversion
 - Ankle dorsiflexion
 - Ankle plantarflexion
 - Ankle eversion
30. What is the most common reason for persistent symptoms after an ankle injury?
- Underlying fracture
 - Cartilage injury
 - Fat pad necrosis
 - Inadequate or incorrect treatment
31. The definitive exam used to evaluate for ACL tear is?
- Pivot shift
 - Anterior drawer test
 - Sag sign
 - Lachman's test
32. A positive Thompson's test is suggestive of which injury?
- High ankle sprain
 - Achilles tendon rupture
 - Patellofemoral syndrome
 - Lateral ankle sprain
33. A Q-angle greater than 10° in males or 15° in females predisposes to what problem?
- ACL tears
 - LCL tears
 - Baker's cysts
 - Patellofemoral syndrome
34. What is the likelihood of having an ACL tear if a "pop" was felt or heard during a twisting knee injury?
- ~10%
 - ~25%
 - ~60%
 - ~80%
35. Weakness with resisted dorsiflexion of the ankle suggests injury to which muscle?
- Tibialis posterior
 - Gastrocnemius
 - Tibialis anterior
 - Peroneal longus



American Academy
of Family Physicians

Examination of the Musculoskeletal System Self-study Program *Answer Sheet*

Name: _____ AAFP ID#: _____

Address: _____

City: _____ State: _____ Zip: _____

- | | | | |
|----------|-----------|-----------|-----------|
| 1. _____ | 10. _____ | 19. _____ | 28. _____ |
| 2. _____ | 11. _____ | 20. _____ | 29. _____ |
| 3. _____ | 12. _____ | 21. _____ | 30. _____ |
| 4. _____ | 13. _____ | 22. _____ | 31. _____ |
| 5. _____ | 14. _____ | 23. _____ | 32. _____ |
| 6. _____ | 15. _____ | 24. _____ | 33. _____ |
| 7. _____ | 16. _____ | 25. _____ | 34. _____ |
| 8. _____ | 17. _____ | 26. _____ | 35. _____ |
| 9. _____ | 18. _____ | 27. _____ | |

Return completed test to:
Kevin McDaniel
Senior CME Program Coordinator
American Academy of Family Physicians
11400 Tomahawk Creek Parkway
Leawood, KS 66211

Examination of the Musculoskeletal System Self-study Program

Answers

- | | | | |
|------|-------|-------|-------|
| 1. c | 10. c | 19. b | 28. d |
| 2. d | 11. c | 20. d | 29. d |
| 3. a | 12. a | 21. a | 30. d |
| 4. c | 13. a | 22. a | 31. d |
| 5. c | 14. d | 23. d | 32. b |
| 6. d | 15. c | 24. d | 33. d |
| 7. a | 16. b | 25. d | 34. d |
| 8. a | 17. c | 26. a | 35. c |
| 9. d | 18. d | 27. a | |